

---

# Photodynamic Therapy for Barrett's Esophagus

Masoud Panjehpour · Bergein F. Overholt

Center of Excellence for Treatment of Barrett's Esophagus, Thompson Cancer Survival Center, Knoxville, Tenn., USA

---

## Abstract

Barrett's esophagus is a premalignant condition associated with gastroesophageal reflux disease where the normal squamous lining is replaced by specialized columnar mucosa. For many years, esophagectomy was the standard treatment for Barrett's patients with high-grade dysplasia or early cancer. Photodynamic therapy (PDT) offers an alternative outpatient endoscopic procedure that eliminates dysplasia and superficial cancer while reducing the risks of complications compared to esophagectomy. Guidelines for the application of PDT in the management of Barrett's esophagus with high grade dysplasia are provided. Detailed discussion is provided on patient selection, treatment delivery techniques, follow-up endoscopy strategies for efficacy evaluation, potential side effects and complications, and management of post-PDT strictures. A brief discussion of clinical outcomes in single-center and multicenter studies is presented.

Copyright © 2010 S. Karger AG, Basel

Barrett's esophagus (BE) is a precancerous condition associated with gastroesophageal reflux disease where the normal squamous lining is replaced by specialized columnar mucosa. BE is associated with an increased risk of mucosal dysplasia and cancer with a 30- to 120-fold increase in the occurrence of adenocarcinoma compared to the normal population [1–3].

For many years, esophagectomy was the standard treatment for Barrett's patients with high-grade dysplasia (HGD) or early cancer. Esophagectomy is associated with a 40–50% risk of major complications and a mortality rate of 3–5% at high-volume centers and up to 20% at low-volume hospitals [4–10]. Photodynamic therapy (PDT) offers an alternative outpatient endoscopic procedure that eliminates dysplasia and superficial cancer and reduces the length of Barrett's mucosa while reducing risks compared to esophagectomy [11–16]. PDT utilizes the photochemical reaction between a photosensitizing drug, light and tissue oxygen. Interaction of the three components results in production of singlet oxygen and free radicals that are highly cytotoxic, resulting in the ablation of illuminated tissue. Porfimer sodium is a photosensitizer that has been used effectively for PDT of HGD and early cancer in BE when delivered concurrently with effective acid-suppression therapy [15–17].

This chapter will provide the technique and guidelines for the application of PDT for management of BE with HGD. Special emphasis will be made by providing information on the technique that has been approved by the FDA [15]. Throughout the chapter, we will provide comparisons between the FDA-approved technique and the relevant data published during phases of the development to clarify any confusion.

## Techniques

### *Patient Selection*

All patients must have an endoscopy with 4 quadrant large-particle biopsies every 1–2 cm. Biopsy results should be confirmed by an expert GI pathologist trained in Barrett's diagnosis. Patients with nodular disease should have endoscopic ultrasound (EUS) for evaluation of esophageal wall layers (either intact or thickened) as well as examination of adjacent lymph nodes. Patients with abnormal appearing nodes or nodes larger than 1 cm should undergo fine needle aspiration. Patients with T1 mucosal lesions should have an endoscopic mucosal resection (EMR) [18] followed in 4–8 weeks with PDT to treat the remaining Barrett's mucosa. Pathological evaluation of lesions removed during EMR is a valuable tool for planning treatment strategy. Patients with lesions extending into the submucosa or deeper layers should be referred for surgical intervention. If patients are denied esophagectomy, they may be treated with PDT. Prior to availability of EMR, T1 mucosal lesions received an extra light dose using a small cylindrical diffuser before the entire area was treated using the balloon for 'field PDT'. If EMR is not performed, an extra light dose targeted to the nodular area is recommended [12, 15]. This will be discussed in more detail later.

### *Photodynamic Therapy*

Before delivery of PDT, a thorough history and physical examination including laboratory work, chest X-ray and ECG should be performed. Patients with known porphyria or known hypersensitivity to porphyrins should not be treated.

### *Administration of Porfimer Sodium and Application of PDT*

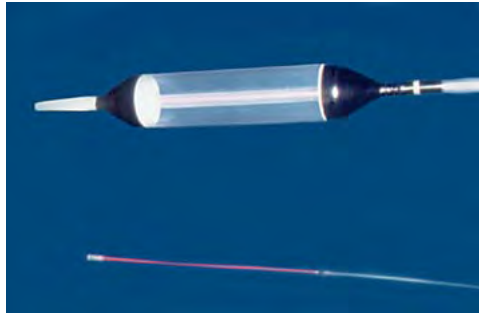
Patients may be treated as outpatient. All patients receive an intravenous (2 mg/kg) injection of porfimer sodium (Photofrin®, Axcan Pharma, Mont-Saint-Hilaire, Que., Canada). Two to three days after drug injection, 630 nm light from a KTP/dye laser (Laserscope, San Jose, Calif., USA), a diode laser (Diomed, Andover, Mass., USA) (fig. 1) or an argon-pumped dye-laser (Lumenis, (previously Coherent), Santa Clara, Calif., USA) is delivered using an Xcell PDT balloon (Wilson-Cook Medical, Winston Salem, N.C., USA). This is a 25-mm diameter esophageal PDT balloon that is provided with window lengths of 3, 5 and 7 cm. These balloons come with a matching cylindrical diffuser to be inserted into the balloon. The length of the cylindrical diffuser is always 2 cm longer than the window length (fig. 2). Therefore, 3-, 5- and 7-cm windowed balloons are used with 5-, 7- or 9-cm cylindrical diffusers, respectively. The balloon is positioned in the esophagus over a guide wire. The position of the balloon window should be monitored using an endoscope passed along side the shaft of the balloon (fig. 3). A yellow marker on the balloon shaft (located 3 cm proximal to the edge of the window) allows proper positioning of the window where treatment is to be delivered.

The Xcell PDT balloon has a reflective inner surface which was used in the multicenter study and subsequently approved by the FDA for treatment of HGD in BE [15]. The reflective balloon was developed to improve the uniformity of the light along the length of the window. A comprehensive discussion of different light-delivery devices has been published elsewhere [19].



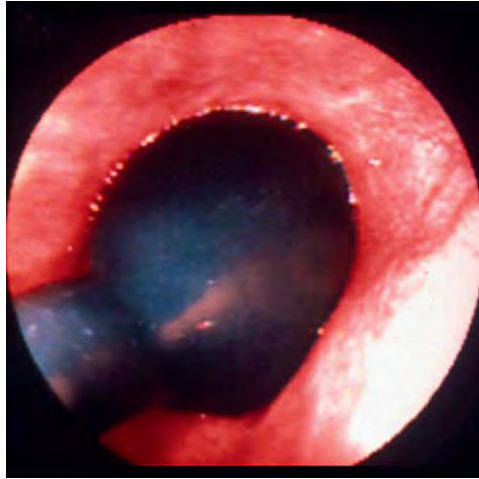
1

**Fig. 1.** Diomed PDT laser.



2

**Fig. 2.** Xcell PDT balloon (top) and cylindrical diffuser (bottom).



3

**Fig. 3.** Endoscopic monitoring of PDT balloon during treatment.

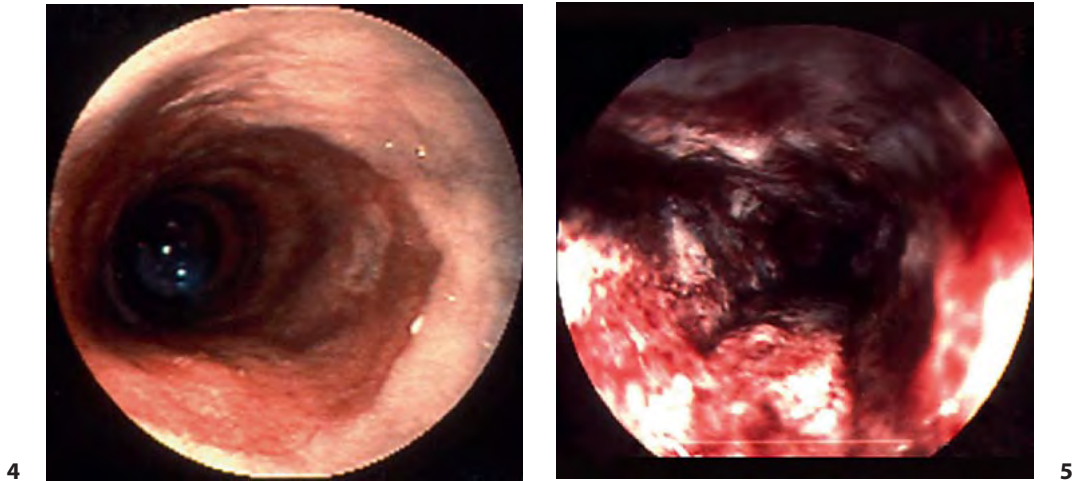
### *Handling of the Balloon for PDT*

When choosing the length of balloon window, at least 0.5–1 cm of normal tissue should be included in the treatment field at both the proximal and distal margin of BE to assure proper targeting of the affected mucosa. This is important due to inadvertent movement of the balloon in the esophagus during treatment. The 5- and 7-cm balloons are most commonly used for treatment. Due to the length of a typical Barrett's segment and constant movement, a 3-cm windowed balloon is used infrequently. A maximum of 7 cm of Barrett's mucosa may be treated in one session.

The balloon inflation should start with a pressure of 80–100 mm Hg to fully inflate and flatten the esophageal folds, followed by reduction to 20 mm Hg immediately before initiation of laser treatment. While high balloon pressure is desired to keep the balloon fully inflated, it has the potential to press against the esophageal wall, affecting blood flow to the treatment area. The reduction in blood flow lowers the oxygen concentration in tissue, which in turn reduces the PDT injury [20]. In our earlier studies, we used higher balloon pressures which frequently resulted in areas of mild injury (called skipped areas). Gradual reduction of the inflation pressure in subsequent patients proved effective in eliminating the majority of skip areas [11].

### *Calculation of Energy Density*

Patients should be treated using an energy density dose of 130 J/cm. If possible, the power density should be set at 270 mW/cm of cylindrical diffuser length. This would mean that a total power of 2,430 mW is required when using a 9-cm cylindrical diffuser in a 7-cm balloon (270 mW/



**Fig. 4.** Barrett's esophagus at the level of squamo-columnar junction before PDT. **Fig. 5.** Barrett's esophagus 48 h after PDT showing severe hemorrhagic necrosis.

cm × 9 cm). The illumination time is calculated by dividing the energy density (in J/cm) by the power density (in W/cm). For example, using the power density of 270 mW/cm, it requires 480 s to deliver a light dose of 130 J/cm ( $130 \text{ J/cm} \div 0.27 \text{ W/cm}$ ). Some lasers (such as Diomed Laser) do not provide sufficient output power to deliver 2,430 mW from a 9-cm cylindrical diffuser. In such cases, the power density of 200 mW/cm may be used. Therefore, the total power from a 9-cm diffuser is reduced to 1,800 mW ( $200 \text{ mW/cm} \times 9 \text{ cm}$ ). Using a power density of 200 mW/cm, a 650-second illumination is required to deliver 130 J/cm. Power densities lower than 200 mW/cm require illumination times that become impractical. For example, using a power density of 150 mW/cm (or 0.15 W/cm), it requires 866 s to deliver 130 J/cm ( $130 \text{ J/cm} \div 0.15 \text{ W/cm}$ ).

It should be noted that light dosimetry, associated with the non-reflective balloon [11, 12, 16] used in previous phases of protocol development, was different from that used with the Xcell reflective PDT balloon and should not be confused. The optimum energy density delivered using the non-reflective balloon was 200 J/cm. The power density was 400 mW/cm which required 500 s to deliver a treatment. The equivalency studies to compare non-reflective and reflective balloons were performed in canine esophagus by measuring the actual light dose delivered to the mucosa using isotropic probes attached to the outside of the balloon window (unpublished preclinical studies).

Prior to EMR or in patients not suitable for EMR, patients with a nodular area within the BE should be treated with an extra 50 J/cm targeted to the nodule using a short cylindrical diffuser before 'field' delivery of 130 J/cm using the Xcell PDT balloon. The power density from short cylindrical diffusers should be set at 400 mW/cm. For example, using a 2.5-cm diffuser, the total power will be 1,000 mW ( $2.5 \text{ cm} \times 400 \text{ mW/cm}$ ) from the diffuser. Delivery of 50 J/cm at the power density of 400 mW/cm, requires 125 s of illumination time ( $50 \text{ J/cm} \div 0.4 \text{ W/cm}$ ). The dose of 50 J/cm was selected and tested during protocol development and proved to be a safe dose as a boost to the balloon treatment [12, 15].

Proper light dosimetry requires accurate measurement of laser power. When using the Diomed laser, an internal power meter is provided which must be used for calibration of the fiber and setting the power. An external integrating sphere power meter (with a large-diameter

sphere) should be used when using Laserscope or Lumenis lasers. Currently, UDT Instruments (Model 371, Baltimore, Md., USA) manufactures a power meter that is specifically designed for PDT. One should be aware that the power meter provided with the Laserscope PDT system is not recommend for use with a cylindrical diffuser longer than 3 cm.

#### *Post-PDT EGD*

Two days after laser treatment, the mucosal injury should be evaluated endoscopically. Figures 4 and 5 show endoscopic views of Barrett's esophagus prior to and 48 hrs after PDT, respectively. A supplemental dose of 50 J/cm (or more at the discretion of physician) [12, 15] may be delivered to areas with mild response using a short cylindrical diffuser inserted through the biopsy channel of the scope. Also at the discretion of the physician, if a patient with Barrett's segment longer than 6–7 cm is doing well and is clinically stable at the 48-hour follow-up, additional treatment may be delivered to the untreated segment using the standard light dose. The additional treatment will likely produce more post-procedure discomfort. Treatment overlap should be avoided to reduce the risk of excessive treatment of the previously treated area, which may increase the risk of stricture development. Since the diffuser is used for most of the retreatments, the physician should recognize that the diffuser light extends distally from the tip of the diffuser and will create a treatment effect for an additional 0.5–1.0 cm from the end of the diffuser.

#### *Special Precautions*

After the treatment, most patients experience some chest pain, nausea and low-grade fever for 3–7 days. Following PDT, oral narcotics may be given to control chest discomfort in addition to antiemetics for nausea. Acetaminophen may be taken for low-grade fever as needed.

Prophylactic intravenous hydration over the first 12–24 h should be considered to prevent dehydration in some patients. Typically, patients remain on liquids and soft foods for several days after laser treatment. Patients may return to a normal diet as tolerated. Most patients return to a normal diet within 2–3 weeks.

An effective acid-suppression protocol is extremely important after endoscopic ablation of Barrett's mucosa [15, 21]. Patients should use high-dose proton pump inhibitor (PPI) therapy twice daily beginning several days before PDT and for at least 3 months after the treatment. On the day of laser treatment, gastric pH can be checked. If the pH is 4 or less, the dose of PPI should be doubled and pH checked during the 48-hour follow-up endoscopy to assess the effectiveness of PPI therapy. We recommend that patients remain on high-dose PPI therapy for at least 1 year after they have been fully cleared of Barrett's mucosa. Thereafter, patients may reduce their dose to once daily. If their symptoms are controlled, they may continue with daily PPI medication. We recommend long-term PPI treatment for all patients. If a patient is an operative candidate, surgical (laparoscopic) repair of a hiatal hernia may be recommended.

#### *Evaluation of Treatment Efficacy*

All patients should undergo surveillance EGD 3 months after PDT to allow complete healing of the treated area. The 3-month follow-up consists of 2 endoscopy procedures. The first endoscopy should include visual examination of the treated area: Lugol's, Fujinon intelligent color enhancement or narrow-banding imaging chromoendoscopy to detect small islands of Barrett's mucosa, and 4 quadrant large-particle biopsies every 2 cm of the treated and untreated areas, if

any. Large-particle biopsies are preferable to detect any subsquamous Barrett's. A second endoscopy with thermal ablation may be performed in patients who have residual Barrett's mucosa. Endoscopy with biopsies (and possible ablation) should be repeated at 6-month intervals for at least 2 years. When possible, patients should be followed for at least 5 years [16].

### *Supplemental Treatments during Follow-Up Endoscopies*

On follow-up endoscopies, residual small islands of Barrett's mucosa may be found within the treated area. These islands should be biopsied carefully. Thermal ablation techniques such as Nd:YAG contact laser [11] and argon plasma coagulation [14] may be used to ablate the residual Barrett's mucosa. In our institution, we use a contact Nd:YAG laser which allows accurate targeted treatment of small islands of residual Barrett's mucosa within the treated field or untreated Barrett's mucosa (outside the treated field). If the residual segment does not contain HGD, then thermal ablation may be used to treat that area during subsequent visits. If HGD is present, additional PDT, mucosal resection or, in some cases, aggressive thermal ablation should be considered. We repeat PDT a maximum of three times.

When a second PDT is delivered, overlapping of the first and second fields should be avoided, if possible. This strategy would reduce the risk of stricture development seen with overlapping of the PDT fields [11].

### *Management of Esophageal Strictures after PDT*

One of the complications after PDT for BE is formation of strictures which occur more frequently in long-segment Barrett's or in areas of treatment overlap. Thus, patients should be contacted by phone weekly. Dysphagia may be diagnosed by persistent difficulty in swallowing solid foods over several days. Those with documented dysphagia should be assessed by endoscopy for the presence of a stricture. In some patients, dysphagia may be due to transient esophageal spasms. While others have reported [22] abnormal esophageal motility following PDT, we consider persistent solid food dysphagia a symptom highly suggestive of stricture formation. The length of strictures are typically short, ranging from 1–2 cm. Esophageal strictures typically occur 3–4 weeks after PDT. If a stricture is present, dilations should be performed twice a week, starting with Savary 33 or 36 until Savary 48–51 is reached, then weekly for several weeks with Savary 51 or 54, then monthly for several months. Methylprednisolone acetate (Depo-medrol, Pharmacia & Upjohn Company) may be injected (20 mg in 4 sites) into the inflamed stricture weekly during each of the first 3 weeks [23].

## **Clinical Outcomes**

### *Efficacy Results of Multicenter Randomized Study*

PDT for BE with HGD received regulatory approval in the US based on the results of a multicenter randomized trial [15] using the techniques described here. This was a report on a minimum 2-year follow-up of a 2:1 randomized controlled trial of Ps-PDT plus omeprazole (treatment

arm) versus omeprazole only (control arm) in the treatment of Barrett's HGD. The study enrolled 208 patients with 138 in the PDT treatment arm and 70 in the control arm. At the end of a minimum 24-month follow-up, PDT plus omeprazole showed statistically significant improvement in elimination of HGD and in the reduction of the incidence of adenocarcinoma compared to the control arm. Ablation of all HGD was noted in 77% of patients in the PDT arm versus 39% in the control arm. Complete ablation of all Barrett's epithelium and dysplasia was achieved in 52% of patients in the PDT group vs. 7% in the control arm. A reduction in the progression to cancer from 28% in the control arm to 13% in the PDT arm was found. It is noted that during the follow-up biopsies, any pathologic interpretation that raised any suggestion of cancer, e.g. 'cannot rule out adenocarcinoma', was classified as progression to cancer in these patients. It should also be noted that no adjuvant therapy such as Nd:YAG laser or argon plasma coagulation was used to treat residual Barrett's mucosa upon follow-up endoscopy during the study. The landmark 5-year follow-up study confirmed the 2-year results [24]. This study demonstrated the long-term durability of the treatment results found at the 2-year follow-up. At 5 years, PDT was still significantly more effective than PPI alone in eliminating HGD (77 vs. 39%). Similarly, the reduction in progression to cancer remained similar to that reported at the 2-year follow-up. There was a 15% likelihood of cancer occurring in the PDT arm versus 29% in those receiving PPI alone. There was also a significantly longer time in progression to cancer in the PDT group.

It is noted that at the time of this writing, PDT is the only ablation treatment for Barrett's HGD that has been evaluated in a 5-year randomized controlled multicenter trial.

Squamous overgrowth in Barrett's patients receiving PDT under the multicenter randomized study was evaluated in 33,658 biopsy samples at the 5-year follow-up [25]. This study demonstrated no significant difference in squamous overgrowth comparing patients receiving PDT/PPI versus those received PPI alone. In no patient was the worst follow-up pathology located in subsquamous Barrett's.

### *Efficacy Results in Single-Center Studies*

While results of the multicenter randomized study best represent the expected outcome from the technique described here, one should be familiar with the relevant publications on porfimer sodium PDT for BE [11–14].

Overholt et al. [11] reported on the treatment of 100 patients with Barrett's dysplasia including 13 with superficial cancers using porfimer sodium PDT. They used either a non-reflective balloon or cylindrical diffusers alone to deliver a light dose of 100–250 J/cm. All patients were on long-term PPI therapy. The Nd:YAG laser was used to ablate small residual areas of Barrett's mucosa. Patients were followed for 4–84 (mean 19) months. Conversion of approximately 75–80% of treated Barrett's mucosa to normal squamous epithelium was found in all patients with complete elimination in 43 patients. Dysplasia was eliminated in 78 patients. Ten of the 13 malignancies were ablated. Of clinical importance, in their initial work PDT was directed only to the dysplastic segment of Barrett's mucosa. Dysplasia developed during follow-up in 11 of 48 patients in *untreated* Barrett's mucosa requiring additional therapy, indicating the need for complete ablation of Barrett's mucosa in such patients.

Panjehpour et al. [12] used a 5- or 7-cm non-reflective PDT balloon and Nd:YAG thermal ablation in 60 patients with BE with low-grade dysplasia, HGD and early cancer. Patients were followed for 3–18 (mean 9.8) months. While the protocol was designed to deliver 175 J/cm for

low-grade dysplasia and 200 J/cm for HGD, the majority of patients received 200 J/cm due to a history of high grade or the presence of nodular disease. Nodular areas received an extra light dose of 50–75 J/cm using a short diffuser prior to balloon treatment. Balloon pressure was maintained between 20 and 30 mm Hg during laser delivery. They reported ablation of cancer in all patients, and elimination of HGD in 96% of patients. Cancer and dysplasia were eliminated in 77% of patients. Barrett's mucosa was totally eliminated in 42% of patients. The overall length of Barrett's segment was reduced by 5.22 cm. Wang [13] used a hematoporphyrin derivative as the photosensitizer and short cylindrical diffusers passed through the biopsy channel of the endoscope. Using a light dose of 200 J/cm, they treated 26 patients and achieved elimination of HGD in 88%. Elimination of Barrett's mucosa was seen in 35% of patients. Wolfsen et al. [14] reported results of porfimer sodium PDT in 102 patients with HGD and mucosal adenocarcinoma. The median follow-up was 1.6 years. They used 2.5- to 5.0-cm cylindrical diffusers passed through the endoscope and delivered a light dose of 150–225 J/cm. Using a single dose of PDT, complete ablation of Barrett's epithelium was obtained in 56% of patients. They used an argon plasma coagulator to ablate the residual Barrett's mucosa in the remaining patients. Four patients (4%) had incomplete ablation of Barrett's mucosa. In 3 patients, subsquamous HGD and carcinoma were detected. Esophagectomy was used to successfully resect the intramucosal cancer without any evidence of submucosal or lymph involvements. The 4th patient had previously undergone EMR documenting intramucosal carcinoma with an extensive thermal effect limiting evaluation of deeper tissue layers. CT and EUS demonstrated abnormal lymphadenopathy. Despite radiation and chemotherapy, the patient developed metastatic adenocarcinoma.

Long-term results of single-center studies for BE have also been reported. Overholt et al. [16] reported on 103 patients in a phase I/II study evaluating porfimer-PDT in the treatment of Barrett's dysplasia or early cancer using cylindrical diffusers or non-reflective balloon. 82 patients completed a mean follow-up of 58.5 (range 41–132) months. Following PDT, the length of Barrett's mucosa decreased by a mean 6.92 (range 1–22) cm. 56 of 82 patients (68%) had elimination of Barrett's mucosa. Of the 65 patients with HGD followed for the entire 5-year follow-up, 60 (94%) had elimination of HGD.

Three (4.6%) patients developed subsquamous adenocarcinoma. The first case was diagnosed 6 months after PDT. The authors believe the cancer was preexisting and that the initial PDT did not clear the lesion. The patient was non-operative and was therefore treated with PDT a second time. The lesion was cleared and the patient remained free of disease when last seen 3 years after the second PDT session. In 2 patients, subsquamous cancer was found 5 years after PDT. Both patients had initially been cleared of all Barrett's as determined by biopsies on their previous 2 annual examinations. Interestingly, both cancers were 1–3 mm in size, were endoscopically visualized as small submucosal nodules and both occurred within 1–2 cm of the neo-squamo-columnar junction. Both patients had reduced their PPI medications over the preceding 1–2 years. One was retreated with PDT and was clear 2 years after retreatment. The 3rd patient was treated with brachytherapy but died 6 months later. Based on the medical and surgical literature, an expected incidence of cancer in these 65 patients with HGD followed over a 5-year period after treatment would be expected to be between 16 and 32, indicating a significant reduction in the incidence of cancer in patients with HGD treated with PDT, thermal ablation and PPI therapy. Subsquamous, non-dysplastic metaplastic epithelium was found in 4 patients (4.9%). It should be noted that these patients were treated at different stages of protocol development which included optimization of different treatment parameters such as light dose and balloon pressure, two very important parameters.

**Table 1.** Side effects and complications of PDT

Side effects	Incidence, %
Chest pain	20
Nausea	11
Vomiting	32
Constipation	13
Dysphagia	19
Dehydration	12
Hiccups	10
Atrial fibrillation	1–3
Photosensitivity reaction	7–18
Esophageal perforation	<1 <sup>a</sup>
Pleural effusion	2 <sup>b</sup>
Esophageal strictures	36 <sup>c</sup>

Data are based mainly on the results of a large multicenter study [15].

<sup>a</sup> Not reported in the multicenter study [15]. One esophageal perforation reported by Wolfson et al. [14] possibly due to vomiting.

<sup>b</sup> Pleural effusions typically clear spontaneously over several weeks [11].

<sup>c</sup> 12% after 1 PDT, 32% after 2 treatments and 9% after a 3rd treatment.

### *Potential Side Effects/Complications*

The side effects and complications reported in the multicenter study best represent the expected incidences using the PDT techniques described here [15] (table 1).

During the multicenter randomized study [15], patients reported chest pain (20%), nausea (11%), vomiting (32%), constipation (13%), dysphagia (19%), dehydration (12%), and hiccups (10%). While not reported in the multicenter study, we also typically see patients running a low-grade fever following PDT. Chest pain, nausea and vomiting and dysphagia were transient and were controlled with medications. Overall, 36% of patients developed strictures which were managed successfully with dilations. 12% of patients developed strictures after 1 PDT as opposed to 32% from 2 treatments and 9% after a 3rd treatment [15]. Others have reported different incidence rates for esophageal strictures in single-center studies. Overholt et al. [11] reported overall esophageal strictures in 34% of patients.

The incidence of strictures appears to be dependent on the delivery technique of PDT, such as type and length of balloons, as well as the number of PDT sessions applied. Overholt et al. [16] reported that use of longer centering balloons reduced the incidence of strictures possibly due to elimination of treatment overlaps when using sequential PDTs using short balloons. In another publication, Overholt et al. [16] reported strictures in 18% of patients who received 1 PDT and 50% of those who received 2 PDT treatments, 30% overall. Using a light dose of 200 J/cm, Panjehpour et al. [12] reported an overall 31% esophageal strictures using 7-cm and 7% strictures using 5-cm

non-reflective balloons. Additionally, they reported no improvement in the rate of stricture formation when oral steroids were administered after PDT. Wang [13] reported strictures in 27% of patients treated with a hematoporphyrin derivative and cylindrical diffusers. Wolfsen et al. [14] reported strictures requiring dilations in 20% of patients. A median of 5 dilation procedures were needed to restore stable lumen patency.

Photosensitivity reaction is the main drawback of porfimer sodium PDT. In the multicenter study [15], sunburn-like reactions affected mostly the skin of the face, hands and neck. The majority of reactions were mild and resolved without any medical intervention. 7% of cases had severe reactions. Wolfsen et al. [14] reported skin phototoxicity in 18% of patients due to inadvertent exposure to sun light. Severe reactions may require treatment including steroids to reduce the symptoms. Patients receiving porfimer sodium must protect their skin and eyes from sun and bright lights for at least 30 and up to 90 days. The importance of proper patient education on photosensitivity cannot be overemphasized.

Other complications have been reported in publications prior to the multicenter trial. There is a small (1–3%) risk of atrial fibrillation after PDT. No atrial fibrillations were reported in the 138 patients treated during the multicenter study [15]. In a series of 100 patients treated during the initial phase of protocol development, 3 patients developed atrial fibrillation [11]. All cases responded to medical intervention. In a series of 102 patients, Wolfsen et al. [14] reported atrial fibrillation in 1 patient who received PDT treatment to a 15-cm length of BE. Cardiac evaluation did not reveal any significant underlying coronary artery disease. The patient responded to oral anticoagulant therapy and converted spontaneously to normal sinus rhythm. Another patient with significant coronary artery disease and a history of heart failure developed recurrent congestive heart failure after a 12-cm segment of BE had been treated. This patient required hospitalization and responded to medical intervention. In a series of 12 patients treated by Overholt et al. [26] evaluation of cardiac enzymes and ECG demonstrated no myocardial abnormalities. It should be noted that treatment parameters in the multicenter study [15] were optimized compared to those patients treated in the initial phases of the study using different light delivery devices, higher light doses, and long treatment segments [11, 14]. We believe atrial fibrillation is related to the depth and extent of esophageal injury and the associated inflammation resulting in some underlying cardiac conduction disturbance. Atrial fibrillation occurs only in cases treated at the level of the left atrium.

Although perforation of the esophagus is another potential complication, no perforation was reported in the multicenter randomized study using the balloon light delivery technique [15]. However, using the diffuser light delivery device, Wolfsen et al. [14] reported perforation in 1 patient who was treated for a 7-cm segment of BE. The patient developed severe chest pain within 2 days of PDT. While contrast esophageal radiography showed no sign of the perforation, CT demonstrated free air in the chest and abdomen indicating a transient perforation of gastroesophageal junction possibly due to vomiting. Patient was admitted for observation, bowel rest, and antibiotics. His symptoms completely resolved within a week without the need of surgery.

Small asymptomatic pleural effusions may develop in some patients. In a group of 14 patients who underwent chest X-ray 48 h after PDT, 6 had bilateral plural effusions, 4 had left pleural effusion, 1 had small right plural effusion, and 3 patients had normal chest X-ray [11]. Overall, pleural effusion was symptomatic in 2% of patients requiring thoracentesis [11]. Patients should be monitored closely for signs and symptoms of dyspnea indicating the possibility of pleural effusion, typically detected 2–4 days after PDT. Pleural effusions typically clear spontaneously over several weeks. Oxygen saturation in the high 80s is typical when patients return for their 48-hour follow-up endoscopy.

## Conclusions

Balloon PDT for BE is a scientifically validated outpatient endoscopic treatment that can effectively eliminate Barrett's HGD and reduce the development of cancer. Patient selection should be done carefully to include EUS evaluation of nodular areas. EMR prior to PDT is recommended for nodular areas. High-dose PPI therapy should be administered concurrent with PDT. Long-term follow-up endoscopies should be performed at regular intervals. Chromoendoscopy and adjuvant thermal ablation should be available on follow-up endoscopies for the detection and ablation of residual small islands of Barrett's mucosa. Careful patient education is critical for the management of side effects and to reduce the risk of photosensitivity reactions [27].

## References

- 1 Cameron AJ, Ott BJ, Payne WS: The incidence of adenocarcinoma in columnar-lined (Barrett's) esophagus. *N Engl J Med* 1985;313:857-859.
- 2 Miros M, Kerlin P, Walker N: Only patients with dysplasia progress to adenocarcinoma in Barrett's oesophagus. *Gut* 1991;32:1441-1446.
- 3 Williamson WA, Ellis FH Jr, Gibbs SP, et al: Barrett's esophagus: prevalence and incidence of adenocarcinoma. *Arch Intern Med* 1991;151:2212-2216.
- 4 Birkmeyer JD, Siewers AE, Finlayson EV, et al: Hospital volume and surgical mortality in the United States. *N Engl J Med* 2002;346:1128-1137.
- 5 Bonavina L: Early oesophageal cancer: results of a European multicenter survey. *Group Européen pour l'Etude des Maladies de l'Oesophage*. *Br J Surg* 1995;82:98-101.
- 6 Heitmiller RF, Redmond M, Hamilton SR: Barrett's esophagus with high grade dysplasia. An indication for prophylactic esophagectomy. *Ann Surg* 1996;224:66-71.
- 7 Holsher AH, Bollschweiler E, Schneider PM, Siewert JR: Early adenocarcinoma in Barrett's esophagus. *Br J Surg* 1997;84:1470-1473.
- 8 Nigro JJ, Hagen JA, DeMeester TR, et al: Occult esophageal adenocarcinoma: extent of disease and implications for effective therapy. *Ann Surg* 1999; 230:433-438.
- 9 Rice TW, Falk GW, Achkar E, Petras RE: Surgical management of high grade dysplasia in Barrett's esophagus. *Am J Gastroenterol* 1993;88:1832-1836.
- 10 Thomas P, Doddoli C, Neville P, et al: Esophageal cancer resection in the elderly. *Eur J Cardiothor Surg* 1996; 10:941-946.
- 11 Overholt BF, Panjehpour M, Haydek JM: Photodynamic therapy for Barrett's esophagus: follow-up in 100 patients. *Gastrointest Endosc* 1999;49:1-7.
- 12 Panjehpour M, Overholt BF, Haydek JM, Lee SG: Results of photodynamic therapy for ablation of dysplasia and early cancer in Barrett's esophagus and effect of oral steroids on stricture formation. *Am J Gastroenterol* 2000; 95:2177-2184.
- 13 Wang KK: Current status of photodynamic therapy of Barrett's esophagus. *Gastrointest Endosc* 1999;49: S20-S23.
- 14 Wolfsen HC, Hemminger LL, Wallace MB, Devault KR: Clinical experience of patients undergoing photodynamic therapy for Barrett's dysplasia or cancer. *Aliment Pharmacol Ther* 2004;20:1125-1131.
- 15 Overholt BF, Lightdale CJ, Wang KK, Canto MI, et al: Photodynamic therapy with porfimer sodium for ablation of high-grade dysplasia in Barrett's esophagus: international, partially blinded, randomized phase III trial. *Gastrointest Endosc* 2005;62:488-498.
- 16 Overholt BF, Panjehpour M, Halberg DL: Photodynamic therapy for Barrett's esophagus with dysplasia and/or early stage carcinoma: long-term results. *Gastrointest Endosc* 2003;58:183-188.
- 17 Wolfsen HC: Present status of photodynamic therapy for high grade dysplasia in Barrett's esophagus. *J Clin Gastroenterol* 2005;39:189-202.
- 18 Wang KK: Combined endoscopic mucosal resection and photodynamic therapy for high grade dysplasia and early cancer in Barrett's esophagus. *Tech Gastrointest Endosc* 2005;7:69-72.
- 19 Panjehpour M, Overholt BF, Haydek JM: Light sources and delivery devices for photodynamic therapy in the gastrointestinal tract. *Gastrointest Endosc Clin N Am* 2000;10:513-532.
- 20 Overholt BF, Panjehpour M, DeNovo RC, Peterson MG, Jenkins C: Balloon photodynamic therapy of esophageal cancer: effect of increasing balloon size. *Lasers Surg Med* 1996;18:248-252.

- 21 Brandt LJ, Blansky RL, Kauvar DR: Repeat laser therapy of recurrent Barrett's epithelium: success with anacidity. *Gastrointest Endosc* 1995;41:267.
- 22 Malhi-Chowla N, Wolfsen HC, DeVault KR: Esophageal dysmotility in patients undergoing photodynamic therapy. *Mayo Clin Proc* 2001;76:987-989.
- 23 Overholt BF, Panjehpour M: Photodynamic therapy techniques for ablation of Barrett's esophagus. *Tech Gastrointest Endosc* 2000;2:203-208.
- 24 Overholt BF, Wang KK, Burdick JS, Lightdale CJ, et al: Five-year efficacy and safety of photodynamic therapy with Photofrin in Barrett's high-grade dysplasia. *Gastrointest Endosc* 2007;66:460-468.
- 25 Bronner MP, Overholt BF, Taylor SL, Haggitt RC, et al: Squamous overgrowth is not a safety concern for photodynamic therapy for Barrett's esophagus with high-grade dysplasia. *Gastroenterology* 2009;136: 56-64.
- 26 Overholt BF, Panjehpour M, Ayres M: Photodynamic therapy for Barrett's esophagus: cardiac effects. *Lasers Surg Med* 1997;21:317-320.
- 27 Phan M, Dyke S, Whittaker MA, Simmerman A, Abrams S, Panjehpour M, Overholt BF: An educational tool for photodynamic therapy of Barrett's esophagus with high-grade dysplasia. *Gastroenterol Nurs* 2005;28:413-419.

Masoud Panjehpour, PhD  
 Center of Excellence for Treatment of Barrett's Esophagus, Thomson Cancer Survival Center  
 1915 White Avenue  
 Knoxville, TN 37916 (USA)  
 Tel. +1 865 541 1628, Fax +1 865 541 1585, E-Mail [mpanjehp@covhlth.com](mailto:mpanjehp@covhlth.com)