

Detachable Snares (Endoloop)

Mohan R. Rengen, DO, and Douglas G. Adler, MD

Endoscopic hemostasis can be achieved by chemical, thermal, and mechanical means. The role of detachable snares or endoloops has been widely described in mechanical hemostasis, and this manuscript reviews their history, indications for use, and the endoscopic techniques involved. Some novel clinical applications for detachable snares will also be reviewed. Clinical evidence supports their use in the management of postpolypectomy bleeding, bleeding from esophageal and gastric varices, and angiodysplasias. Prospective randomized controlled trials utilizing this device are few in number and are still needed to define their role in the field of gastrointestinal endoscopy. *Tech Gastrointest Endosc* 8:12-15 © 2006 Elsevier Inc. All rights reserved.

KEYWORDS gastrointestinal bleeding, hemostasis, detachable snares, endoscopic accessories, polyps, polypectomy

Endoscopic hemostasis of gastrointestinal bleeding can be accomplished by epinephrine injection, thermal coagulation, cryotherapy, and mechanical tamponade. Endoscopic mechanical tamponade can be accomplished by band ligation, clip application, and ligation by a detachable snare loop (Endoloop). Compared with thermal modalities, mechanical tamponade has the unique advantage of avoiding additional tissue injury. The goal of this review is to discuss the applications of endoloop in gastrointestinal endoscopy. The terms “detachable snares” and “loops” will be used interchangeably in this review.

History

Pontecorvo and Pesce (1986) developed the first detachable snare, the “safety snare.”¹ Working in close collaboration with Olympus Optical Corporation, Hachisu developed the first commercially available detachable snare for endoscopic use.²

Detachable Snares

Detachable snares are manufactured by Olympus Medical Corporation (Tokyo, Japan). Three types of detachable snares (nylon loop) devices are available:

- 1 Endo-Loop: A reusable device, which is available in 30-mm and 20-mm opening diameter.
- 2 Poly-Loop: A preassembled ready to use detachable snare with an opening diameter of 30 mm.
- 3 Mini-Loop (Olympus HX-21L; opening diameter of 11 mm) in conjunction with a transparent ligation chamber

(Olympus MH-593) at the end of an endoscope is used for variceal ligation.

Each of these devices is composed of an outer plastic sheath and an inner metal coil around a central cable with a hook that houses the nylon loop. The nylon loop is elliptically shaped and has a silicone-rubber stopper that permits desired amount of tightening of the loop and maintains the tightening.

Device Operation

Detachable Snare

Operation of the device involves four simple steps as shown in the [Figure 1](#).

Mini-Detachable Snare

Operation of this device is similar to the use of a detachable snare except that it requires prelooping of the snare in a ligation chamber attached to the distal end of the endoscope, followed by suction, ligation, and release of the loop ([Fig. 2](#)).

Ligation of Polyps: Technique

Endoscope

An instrument with a minimum working channel of 2.8-mm diameter is required for insertion of an endoloop (outer diameter of endoloop sheath, 2.5 mm). Endoscope with a larger channel is preferred, and a two-channel endoscope allows passage of a grasping forceps through the second channel to maneuver a large polyp into the floppy endoloop.

Positioning the Target Lesion

The target lesion should be positioned at the 5- to 7-o'clock position to facilitate loop placement successfully.

Polyp ligation steps are shown in [Figures 1](#) and [2](#).

Precautions

1. Controlled ligation without transaction.

Tactile sensation alone may not be helpful in deciding when to stop closing the loop. If the ligation is too tight, the polyp can

Division of Gastroenterology and Hepatology, University of Texas-Houston Medical School, Houston, TX.

Address reprint requests to Douglas G. Adler, MD, Director of Gastrointestinal Endoscopy, Assistant Professor of Medicine, University of Texas-Houston Medical School, MSB 4.234, 6431 Fannin, Houston, TX 77030. E-mail: douglas.adler@uth.tmc.edu

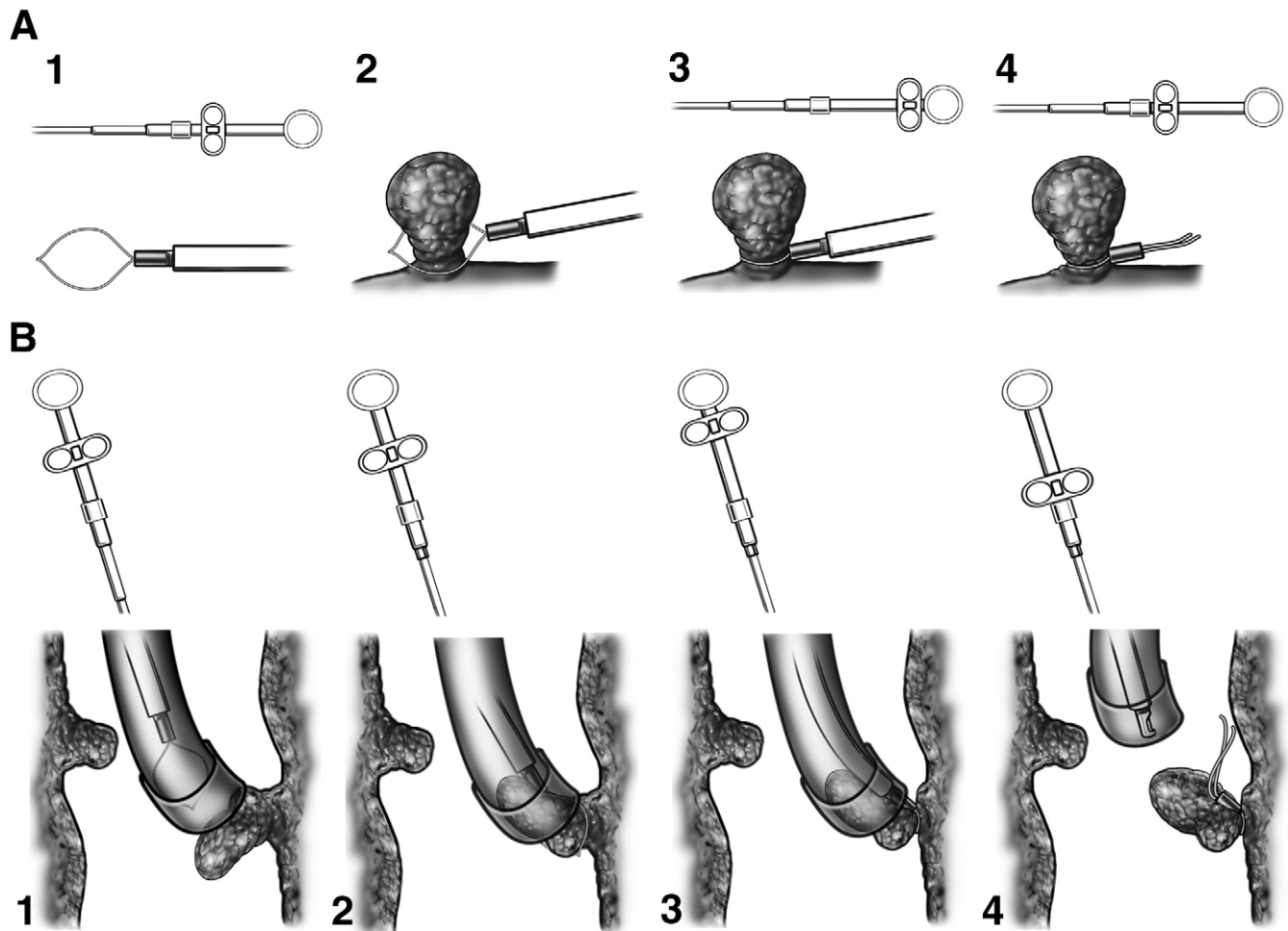


Figure 1 (A) Steps involved in snare ligation of a polyp. (B) Steps for snare ligation of varices.

be transected and precipitate bleeding. Similarly, if the ligation is too loose, the snare is ineffective in preventing or controlling bleeding. Placing a mark on the loop tightening silicon stopper

provides endoscopists the benefit of visual confirmation of snare tightening around the stalk of the polyp, in addition to tactile sensation.³

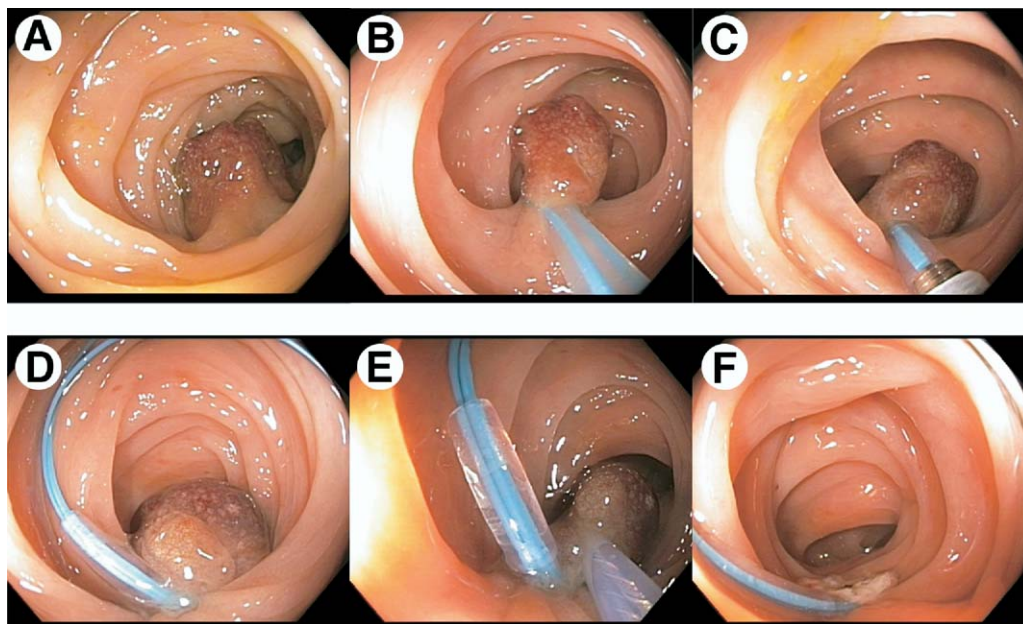


Figure 2 (A) Large pedunculated polyp seen at colonoscopy. (B) Placement of Endoloop around polyp stalk. (C) Tightening of rubber stopper to tamponade any feeder vessels in the polyp stalk. (D) Endoloop fully deployed on polyp stalk. (E) Placement of diathermy snare above endoloop. (F) Endoloop in place following hot snare polypectomy. (Image courtesy of Dr. Roy Soetikno.)

Table 1 Applications of Endo-Loop, Poly-Loop, and Mini-Loop

I. ENDO-LOOP and POLY-LOOP
A. Hemostasis
Postpolypectomy bleeding
Polypoid AVMs
Adjunct to clip hemostasis
B. Ablation
Colonic lipoma
lymphangioma
C. Closure
Colonic and Esophageal Fistula
D. Retrieval
Self-expanding metal stents
II. MINI-LOOP
A. Hemostasis
Esophageal variceal bleeding
Gastric variceal bleeding

2. Avoid endoloop use in thin stalked polyps (<5 mm) and semipedunculated polyps.

Endoloop is likely to transect a thin stalked polyp and precipitate bleeding. Semipedunculated polyp is a relative contraindication as the loop tends to slip off the short stalk after snare polypectomy and may precipitate bleeding.

3. Avoid endoloop use to control of bleeding from a short and residual stalk.

In order for the endoloop to be successful, there should be an adequate length of residual stalk for the endoloop to hold on to it. Short stalk tends to recede and flatten out with dislodgement of the loop. Hence, other techniques such as epinephrine injection and clip application should be considered instead of endoloop ligation in this clinical scenario.

Ligation of Varices:

Technique Using Mini-Detachable Loop

There is no reported experience with this technique in the USA.

Device Assembly

A transparent ligation chamber with a rim on the inside is fitted onto the tip of an endoscope. A mini-detachable, oval-shaped nylon loop with a maximum diameter of 11 mm is inserted into the accessory channel of the endoscope until it opens at the rim of the ligation chamber.

Variceal ligation steps are shown in Figure 2.

Precautions

- 1 Care must be taken to deploy the tails of the deployed loops toward the stomach to avoid interference with the field of view for additional deployment of loops.
- 2 Care must be taken to avoid traction on the varix after ligation and before the release of the loop to avoid tearing of the varix.

Limitations

With the detachable snare already loaded in the endoscope, suctioning of blood becomes limited to clear the field view.

Clinical Applications (Table 1)

Management of Postpolypectomy Bleeding

The mechanism of action of endoloop is by occlusion of the arterial flow in the stalk of a polyp.⁴ Endoloop has been shown to be useful in the prevention of postpolypectomy bleeding,

arrest of active bleeding following polypectomy, and induction of ischemic necrosis of polyps.⁴⁻¹²

Detachable snare ligation is effective in the prevention of postpolypectomy bleeding. In a randomized controlled trial of 89 consecutive patients, Iishi and coworkers have demonstrated a significant reduction of immediate and delayed post polypectomy bleeding and duration of hospitalization in patients undergoing endoloop ligation of the polyp stalk before its resection.⁵

Detachable snare ligation and epinephrine injection are equally effective in the prevention of postpolypectomy bleeding.¹² In a randomized controlled trial of 488 consecutive patients with large pedunculated colorectal polyps (>1 cm), post polypectomy bleeding was reported in 4.3% of the polypectomies: 1.8% (3 of 163 patients) in patients undergoing ligation before snare polypectomy; 3.1% (5 of 161 patients) in patients undergoing epinephrine injection before snare polypectomy; 7.9% (13 of 164 patients) undergoing snare polypectomy alone. In larger polyps (≥ 2 cm), postpolypectomy bleeding occurred in 6.7% (14 of 207 patients): 2.7% in the detachable snare group, 2.9% in the epinephrine injection group, and 15.1% in the control group.¹²

Treatment of Esophageal Variceal Bleeding

Esophageal variceal band ligation using a multi-band ligator is widely used for endoscopic obliteration of varices. Recently, ligation of esophageal varices using mini-loops has been shown to be effective as well.¹³⁻¹⁵

In a randomized controlled trial of 103 patients with recent or active esophageal variceal bleeding, hemostasis was achieved in 6 of 7 (86%) in the mini-detachable snare ligation group and 11 of 13 (85%) in multiple band ligation group with active bleeding; recurrent bleeding after initial treatment occurred in 2 of 46 (5.5%) in the mini-detachable snare ligation group and 3 of 57 (5.3%) in the multiple band ligation group. Esophageal varices were eradicated or reduced to grade I in 4.8 ± 2.1 and 4.5 ± 1.9 sessions in the mini-detachable snare ligation group and multiple band ligation group, respectively. Esophageal variceal recurrence rate was 5 of 46 (11%) and 6 of 57 (11%) in the mini-detachable snare ligation group and multiple band ligation group during a follow-up period of 6 and 16 months, respectively. Although no major complications occurred in either group, minor complications in the mini-detachable snare ligation group included dysphagia, incomplete detachable snare ligation, and variceal bleeding from snare trauma.¹⁴

Naga and coworkers compared the use of mini-detachable snare ligation and multiple band ligation in 50 patients with acute esophageal variceal bleeding. There was no significant difference between the 2 groups in terms of frequency of variceal eradication, variceal recurrence, variceal rebleeding, and cost of care.¹⁵

Although there are certain technical advantages for endoloop ligation, such as better field of vision, tighter application, good results with junctional varices, and a lack of strain exerted by the device on the endoscope, it is unlikely to replace endoscopic band ligation in the management of esophageal varices given the simplicity of operation of a band ligation, excellent safety, and efficacy data.

Treatment of Gastric Variceal Bleeding

Experience with endoscopic ligation of gastric varices with mini-detachable snares is limited.¹⁵⁻¹⁸ Yoshida and coworkers were the first to describe the use of detachable snares to treat gastric

varices.¹⁹ Endoscopic ligation of gastric varices is technically challenging, and the risk of ulceration, bleeding, and perforation raises concerns about its widespread acceptance as therapeutic modality in the management of gastric varices.²⁰

Novel Applications

Ligation Assisted Removal of Colonic Lipomas, Lymphangiomas, and Polypoid AVMs

Risk of perforation following snare resection of a large lipoma with a long pedicle could be avoided by endoloop ligation of the base of a lipoma before snare resection using pure coagulation current.²¹ Large broad-based colonic lymphangioma (3 cm) can be safely removed by snare resection after ligation of the base with an endoloop.²² Endoloop ligation of a large polypoid AVM (3.5 cm) of the colon is useful to cut-off the blood supply before biopsy to establish the diagnosis and plan subsequent therapy.²³

Endoscopic Extraction of Migrated Esophageal Covered SEMS

One or more endoloops can be applied to collapse the migrated self-expandable stent to permit easy removal of the stent.^{24,25}

Adjunct to Clip Hemostasis

Endoloop application has been shown to be successful in the management of bleeding that persists despite the application of clips to a Dieulafoy's lesion and polypectomy site.^{26,27}

Closure of Gastrointestinal Fistula

A combination of a band ligator to create pseudopolyps at the margins of the fistula and endoloops to gather the pseudopolyps and hold them together, followed by application of clips and fibrin glue to close the gap, has been reported to be successful in the closure of chronic fistulae such as pseudocysto-colonic fistula and an esophago-mediastinal fistula.^{28,29}

Peroral Endoscopic Fallopian Tube Ligation

Endoloops have been successfully used to ligate fallopian tubes in an animal experimental study of transgastric endoscopic surgical procedure.³⁰

Conclusions

Detachable snares or endoloops have recently been added to the armamentarium of endoscopic accessories used in endoscopic hemostasis. Clinical evidence supports the use of detachable snares or endoloops in the management of post polypectomy bleeding, bleeding esophageal and gastric varices, and angiodysplasias. In addition, several novel applications of detachable snares and endoloops have been reported in the literature. Large prospective and randomized controlled trials are needed to further define the role of detachable snares in the field of gastroenterology.

References

- Pontecorvo C, Pesce G: The "safety snare": a ligature-placing snare to prevent haemorrhage after transection of large pedunculated polyps. *Endoscopy* 18:55-56, 1986
- Hachisu T: A new detachable snare for hemostasis in the removal of large polyps or other elevated lesions. *Surg Endosc* 5:70-74, 1991
- Tomiki Y, Shinmura K, Maeda T, et al: Pen marking technique for safer polypectomy with detachable snares. *Endoscopy* 37:187, 2005
- Friedland S, Benaron D, Parachikov I, et al: Measurement of mucosal capillary hemoglobin oxygen saturation in the colon by reflectance spectrophotometry. *Gastrointest Endosc* 57:492-497, 2003
- Iishi H, Tatsuta M, Narahara H, et al: Endoscopic resection of large pedunculated colorectal polyps using a detachable snare. *Gastrointest Endosc* 44:594-597, 1996
- Rey JF, Marek TA: Endo-loop in the prevention of the post-polypectomy bleeding: preliminary results. *Gastrointest Endosc* 46:387-389, 1997
- Matsushita M, Hajiro K, Takakuwa H, et al: Ineffective use of a detachable snare for colonoscopic polypectomy of large polyps. *Gastrointest Endosc* 47:496-499, 1998
- Soetikno RM, Friedland S, Lewit V, et al: Lift and ligate: a new technique to treat a bleeding polypectomy stump. *Gastrointest Endosc* 52:681-683, 2000
- Friedland S, Kahng LS, Torosis J, et al: Ligate and let go. *Gastrointest Endosc* 58:473-474, 2003
- Matsushita M, Hajiro K, Okazaki K, et al: A large juvenile polyp in a 1-year-old child safely removed by colonoscopic polypectomy with a detachable snare. *Gastrointest Endosc* 52:118-120, 2000
- Matsushita M, Takakuwa H, Matsubayashi Y, et al: Handcrafted two-channel colonoscope for grasping-forceps-assisted resection of giant pedunculated polyps. *Gastrointest Endosc* 62:132-136, 2005
- Di Giorgio P, De Luca L, Calcagno G, et al: Detachable snare versus epinephrine injection in the prevention of postpolypectomy bleeding: a randomized and controlled study. *Endoscopy* 36:860-863, 2004
- Hepworth CC, Burnham WR, Swain CP: Development and application of endoloops for the treatment of bleeding esophageal varices. *Gastrointest Endosc* 50:677-684, 1999
- Shim CS, Cho JY, Park YJ, et al: Mini-detachable snare ligation for the treatment of esophageal varices. *Gastrointest Endosc* 50:673-676, 1999
- Naga MI, Okasha HH, Foda AR, et al: Detachable endoloop vs. elastic band ligation for bleeding esophageal varices. *Gastrointest Endosc* 59:804-809, 2004
- Harada T, Yoshida T, Shigemitsu T, et al: Therapeutic results of endoscopic variceal ligation for acute bleeding of oesophageal and gastric varices. *J Gastroenterol Hepatol* 12:331-335, 1997
- Cipolletta L, Bianco MA, Rotondano G, et al: Emergency endoscopic ligation of actively bleeding gastric varices with a detachable snare. *Gastrointest Endosc* 47:400-403, 1998
- Yoshida T, Harada T, Shigemitsu T, et al: Endoscopic management of gastric varices using a detachable snare and simultaneous endoscopic sclerotherapy and O-ring ligation. *J Gastroenterol Hepatol* 14:730-735, 1999
- Yoshida T, Hayashi N, Suzumi N, et al: Endoscopic ligation of gastric varices using a detachable snare. *Endoscopy* 26:502-505, 1994
- Lo GH, Lai KH: Is endoscopic ligation therapy with large detachable snares and elastic bands really safe and effective? *Gastrointest Endosc* 57:438-439; author reply 439-440, 2003
- Murray MA, Kwan V, Williams SJ, et al: Detachable nylon loop assisted removal of large clinically significant colonic lipomas. *Gastrointest Endosc* 61:756-759, 2005
- Ajiki T, Nakamura T, Kubota S, et al: Successful endoscopic treatment of colon lymphangioma with a ligating device. *Gastrointest Endosc* 52:800-802, 2000
- Ji JS, Choi KY, Lee BI, et al: A large polypoid arteriovenous malformation of the colon treated with a detachable snare: case report and review of literature. *Gastrointest Endosc* 62:172-175, 2005
- Seitz U, Thonke F, Bohnacker S, et al: Endoscopic extraction of a covered esophageal Z-stent with the aid of Endoloops. *Endoscopy* 30:S91-S92, 1998
- De Ronde T, Martinet JP, Melange M: Easy removal of migrated self-expanding esophageal metal stent using an endoloop device. *Gastrointest Endosc* 52:125-127, 2000
- Uno Y, Satoh K, Tuji K, et al: Endoscopic ligation by means of clip and detachable snare for management of colonic postpolypectomy hemorrhage. *Gastrointest Endosc* 49:113-115, 1999
- Gimeno-Garcia AZ, Parra-Blanco A, Nicolas-Perez D, et al: Management of colonic Dieulafoy lesions with endoscopic mechanical techniques: report of two cases. *Dis Colon Rectum* 47:1539-1543, 2004
- Will U, Meyer F, Hartmeier S, et al: Endoscopic treatment of a pseudocystocolonic fistula by band ligation and endoloop application: case report. *Gastrointest Endosc* 59:581-583, 2004
- Will U, Meyer F, Bosseckert H: Successful endoscopic management of iatrogenic mediastinal infection and subsequent esophagomediastinal fistula, following endosonographically guided fine-needle aspiration biopsy. *Endoscopy* 37:88-90, 2005
- Jagannath SB, Kantsevov SV, Vaughn CA, et al: Peroral transgastric endoscopic ligation of fallopian tubes with long-term survival in a porcine model. *Gastrointest Endosc* 61:449-453, 2005