
Photodynamic Therapy: Palliation and Endoscopic Technique in Cholangiocellular Carcinoma

Tommy Ibrahim · Michel Kahaleh

University of Virginia Health System, Charlottesville, Va., USA

Abstract

Cholangiocarcinoma is the primary malignancy arising from the biliary epithelium. The disease is marked by jaundice, cholestasis, and cholangitis. Over 50% of patients present with advanced stage disease, precluding curative surgical resection as an option of treatment. Typically, prognosis is poor and survival has been measured in months even after biliary decompression. Palliative management has become the standard of care for unresectable disease and has evolved to include the endoscopic approach. Photodynamic therapy (PDT) consists in administration of a photosensitizer followed by local irradiation with laser therapy. It has been used as a means of palliation for bile duct tumors with promising results. Several studies conducted in Europe and the United States have shown a marked improvement in the symptoms of cholestasis, survival, and quality of life. The published experience regarding PDT for cholangiocarcinoma and the steps required to administer this therapy safely are summarized.

Copyright © 2010 S. Karger AG, Basel

Cholangiocarcinoma is the primary malignancy arising from the biliary epithelium of the bile ducts. The incidence rate is 1–2 per 100,000 people per year in the United States [1]. Initially thought to be an uncommon disease, the number of cases being reported annually is climbing [2]. Nearly two thirds of cases of cholangiocarcinoma occur between the ages of 50 and 70, and the tumor appears to have a male predominance [3]. The tumor seems to be the result of an underlying chronic inflammation of the biliary tract. Predisposing conditions include disorders such as primary sclerosing cholangitis, intrahepatic stones and choledocholithiasis, choledochal cysts, liver flukes, and previous exposure to the contrast agent thorium dioxide (Thorotrast) [4].

Complete surgical resection is the only treatment with potential for a cure. Unfortunately, patients usually present with advanced disease, with greater than 50% found to be unresectable at the time of diagnosis [5–7]. The prognosis in advanced disease is dismal, being approximately 3 months without intervention and 4–6 months after palliative biliary decompression [8–13]. Successful palliation of biliary obstruction remains the main goal to reduce morbidity and mortality in these patients with unresectable disease [9, 14].

The approach to biliary decompression has evolved from a surgical approach, to percutaneous drainage, and finally to endoscopic management. Hepaticojejunostomy is associated with

a 30-day postoperative mortality rate between 7 and 24% [15–19]. Furthermore, quality of life was only improved in a minority of patients undergoing surgery because of the time needed to recover [12, 20, 21]. Even after biliary stenting, the prognosis remains grim [22–27]. Adding chemotherapeutic agents to biliary decompression has largely been unsuccessful [28]. Radiotherapy is an area of great controversy with regard to improved outcomes [29]. However, concurrent chemoradiotherapy with helical tomotherapy intensity-modulated radiotherapy and capecitabine, in conjunction with photodynamic therapy (PDT) has been shown to be well tolerated in patients with hilar cholangiocarcinoma [30].

PDT has been gaining increased awareness in the palliative management of cholangiocarcinoma. PDT is a two-step process. Initially, a photosensitizer is administered before the photoradiation process can occur [31]. Photofrin (porfimer sodium, Axcan Pharma Inc., Mont-Saint Hilaire, Que., Canada) has a selective nature and is preferentially retained by neoplastic tissue [32]. Laser application at a specific wavelength starts the activation process by transforming the drug from its neutral ground state into its active excited state. In the presence of oxygen, cytotoxic singlet oxygen species are formed, destroying the dysplastic cells to which they are bound. These free radicals then directly induce apoptosis and necrosis of the tumor cells [33]. Synergistically, nearby vascular channels are also affected, indirectly accelerating the process by cutting off the supply of vital nutrients.

PDT was demonstrated to reduce xenografted human cholangiocarcinoma tumor volume by 60% in a mouse model [34]. Recent reports and randomized controlled studies in which PDT was used as an adjuvant therapy, have shown a significant survival benefit in patients with unresectable cholangiocarcinoma, as well as a significant improvement in the quality of life after PDT and stenting [35–37].

Techniques

The technique used to execute the procedure has become standardized. PDT should be offered to all patients with nonresectable cholangiocarcinoma. Staging can be performed with computed tomography and/or magnetic resonance imaging [36]. Resectability is usually defined according to the criteria of Vauthey and Blumgart [38].

Each patient found to be a candidate for PDT undergoes a thorough educational process. Specific education regarding sun exposure and protection is necessary to avoid severe sun-related phototoxicity and should be provided to all patients prior to the procedure [36].

Endoscopic retrograde cholangiopancreatography (ERCP) is performed using a large channel duodenoscope (TJF-140, TJF-160, and TJF-160VF; Olympus America, Center Valley, Pa., USA) permitting 10-Fr stent placement. After cannulation into the biliary tract, a cholangiogram is performed to help define the anatomic distribution of malignant tissue and the extent of disease within the biliary ducts. Careful opacification of the dilated segments should be performed selectively (fig. 1). Next, selective bougie and balloon dilation of the stricture(s) to be treated are performed to facilitate diffuser placement within the malignant stricture.

Photoactivation is performed at 630 nm with a light dose of 180 J/cm², fluency of 0.250 W/cm² and irradiation time of 750 s (fig. 2). One or more segments can be treated at the discretion of the endoscopist. When the tumor length exceeds the maximal diffuser length, overlap of treated areas should be avoided by a stepwise pull-back of the fiber under radiologic control. Placement of endoprostheses is performed systematically after the photodynamic treatment

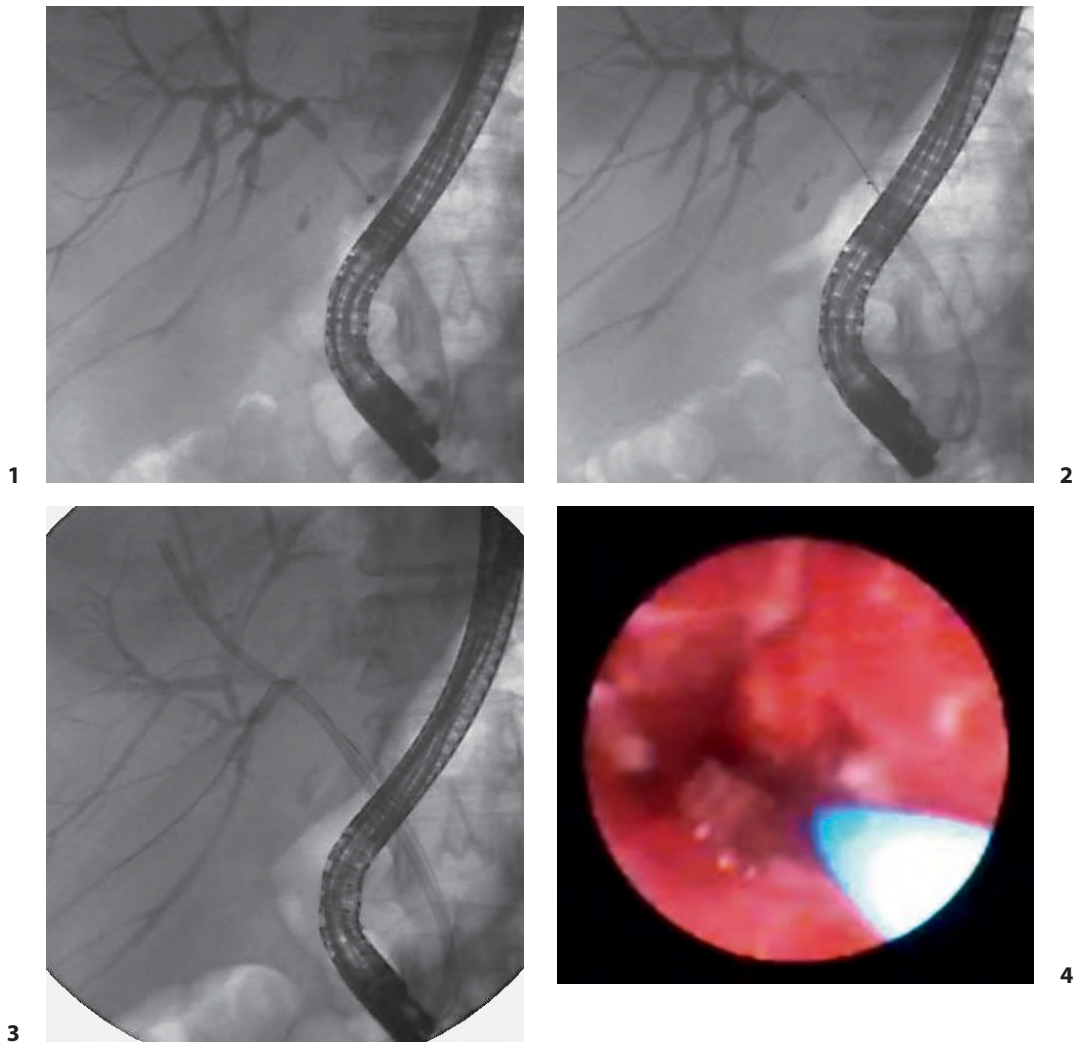
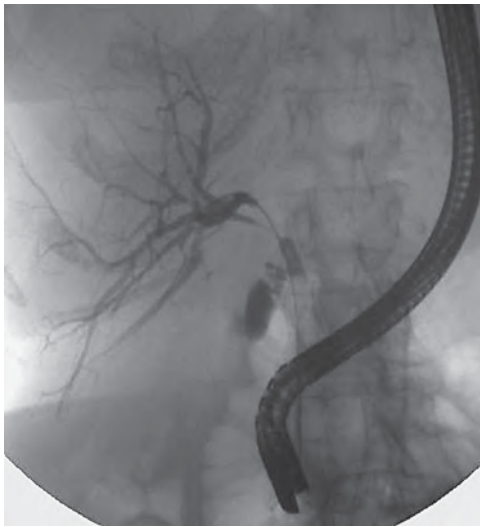


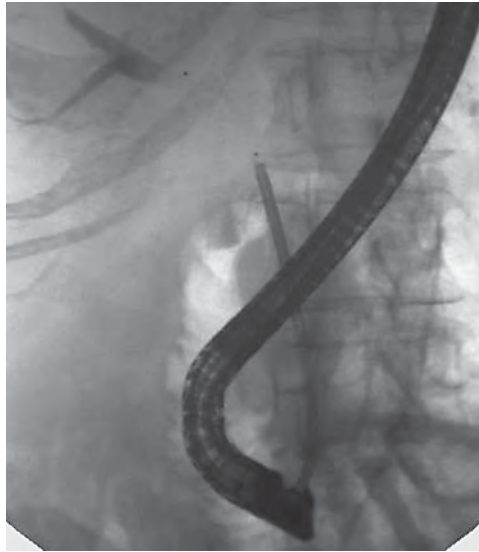Fig. 1. Fluoroscopic image after contrast injection showing a malignant stricture, Bismuth III lesion (patient 1). **Fig. 2.** Fluoroscopic image after advancement of the PDT fiber along side the guidewire through the 10-Fr sheath of a plastic stent delivery system (patient 1). **Fig. 3.** Fluoroscopic images a 8.5-Fr plastic stent across the stricture treated (patient 1). **Fig. 4.** Choledochoscopic images of a malignant stricture at the hilum (patient 2).

to prevent cholangitis (fig. 3). Our group has recently demonstrated the safety and efficacy of choledochoscopy-guided PDT, allowing specific intraductal visualization of the stricture(s) to be treated (fig. 4-6) [37].

Prasad et al. [39] described a technique for PDT using percutaneous biliary access. Patients that failed biliary cannulation or those with preexisting biliary drains were successfully treated using this method [39]. The percutaneous biliary drain was replaced with an 8-Fr vascular sheath over a guidewire. PDT was administered by fluoroscopically guided placement of the cylindrical diffusing fiber. After the treatment was completed, a standard 10-Fr biliary drain was placed to facilitate biliary drainage.



5



6

Fig. 5. Fluoroscopic image of a malignant stricture at the hilum (patient 2). **Fig. 6.** Fluoroscopic image after advancement of the PDT fiber into the malignant stricture through the choledochoscope (patient 2).

PDT is typically repeated at 3-month intervals at which time all stents should be replaced; stents are exchanged earlier in the case of premature occlusion or migration to maintain optimal decompression. All patients should receive perioperative antibiotic prophylaxis, usually with a fluoroquinolone. Postoperatively, patients treated with PDT are advised to remain out of direct sunlight as porfimer sodium may cause prolonged photosensitivity lasting 30–90 days [39].

Accessories

Porfimer sodium is the most commonly used photosensitizer. It is administered intravenously at a dose of 2 mg/kg body weight 48 h prior to illumination. Though other photosensitizers are now available, porfimer sodium is the most studied and the only photosensitizer approved by the FDA. A diode laser system (InGaAlP Laser Diode; Diomed Inc, Andover, Mass., USA) with a maximum power output of 2,000 mW and a wavelength of 630 nm is used as a light source, delivered through a 3.0-m length fiber having a 2.5-cm-long cylindrical diffuser at its distal end (Pioneer Optics, Windsor Locks, Conn., USA). The diffuser can be inserted into a 10-Fr sheath of a plastic stent delivery system (MAJ-1419; Olympus America) and placed at the level of the stricture being treated. Alternatively, our group has been using the choledochoscope as a platform to administer PDT (Spyglass, Boston Scientific, Natick, Mass., USA) [37].

Outcomes

There have been several uncontrolled reports that suggest that PDT can provide a survival benefit (table 1). In 2003, Ortner et al. [31] conducted the first randomized controlled trial comparing survival between biliary stenting alone vs. biliary decompression combined with PDT. After

Table 1. Studies performed using ERCP with PDT with photofrin sodium for palliation of cholangiocarcinoma

Study	Patients n	Study type	Median TB before and after PDT	Mean PDT sessions (range)	Median survival months	Adverse events phototoxicity, cholangitis
Ortner et al. [40], 1998	9	Single arm	18.6 > 6	1.5 (1–2)	14.6	1 (11%), 0 (0%)
Berr et al. [41], 2000	23	Single arm	11.2 > 1.1	3 (1–5)	11.1	3 (13%), 8 (35%)
Rumalia et al. [42], 2001	6	Single arm	2.7 > 1.3	2.3 (1–2)	>6	2 (33%), 2 (33%)
Dumoulin et al. [43], 2003	24	Single arm	13.3 > 2.6	1–2	9.9	2 (8%), 5 (21%)
Ortner et al. [31], 2003	20	Randomized	NA (decreased)	2.4 (1–5)	16.4	2 (10%), 5 (25%)
Ortner et al. [31], 2003	31	Nonrandomized	11.8 > 3.1	1.5 (1–4)	14.2	3 (10%), 6 (19%)
Harewood et al. [44], 2005	8	Single arm	7.7 > 1.1	2 (1–5)	9.2	2(25%), 2(25%)
Witzigmann et al. [45], 2006	68	Single arm	NA (decreased)	2 (1–6)	12	8 (12%), 38 (56%)
Prasad et al. [38], 2007	25	Single arm	6.1 > 3.5	1.6 (1–4)	13.4	1 (4%), 2 (8%)
Kahaleh et al. [36], 2008	19	Comparative	6.3 > 3.5	1.6 (1–3)	16.2	3 (16%), 7 (37%)

TB = Total bilirubin; NA = not available.

carefully examining the initial 39 patients enrolled in the study, improvement in survival and quality of life in the randomized PDT group was found to be very impressive. Patients had a median prolongation of survival of 493 days (n = 20) in the group treated with PDT and stenting vs. a median prolongation of 98 days (n = 19) in the stent-alone group (p < 0.0001). The trial was terminated prematurely as continued data collection and randomization was thought to be unnecessary and ethically unacceptable. The PDT arm of the study showed a clear improvement in cholestasis, physical functioning and global quality of life, keeping patients well integrated in their own social lives. This study was criticized as only patients failing conventional ERCP were enrolled in the study, making a repeat ERCP indispensable which might account for the benefit attributed to PDT.

In 2007, Prasad et al. [39] found that patients with unresectable cholangiocarcinoma without a visible mass benefited from early treatment with PDT. In 2008, our group [36] published their findings comparing stenting alone versus combination therapy of stenting and PDT. Kaplan-Meier analysis demonstrated improved survival in the PDT group compared with the stent-alone group (16.2 vs. 7.4 months, p < 0.004). Mortality in the PDT group at 3, 6, and 12 months was 0, 16, and 56%, respectively. The corresponding mortality in the stent group was 28, 52, and 82%,

respectively. The difference between the 2 groups was statistically significant at 3 and 6 months, but not at 12 months. Although it was not entirely clear whether the benefit was directly related to PDT or the number of ERCP sessions, this key study helped to strengthen the findings published by Ortner et al. [31] in 2003. In that study, not only was there a survival benefit, but overall quality of life was again found to be significantly improved in the PDT group. Furthermore, adverse effects in the PDT group were minor, largely related to phototoxicity, and essentially self-limiting. Other complications occurring included cholangitis, hemobilia, cholecystitis, pancreatitis, duodenal perforation, hepatic abscess and myocardial infarction, were a result of the endoscopic procedure and found in both groups treated [36].

In summary, the majority of patients with cholangiocarcinoma present with advanced and unresectable disease. Treatment needs to be initiated as soon as possible in order to improve survival and quality of life. PDT in conjunction with stenting has shown very promising outcomes. Further multicenter, randomized, prospective controlled trials are needed to confirm the benefit of PDT and stenting compared to stenting alone.

References

- Callery MR, Meyers WC: Bile duct cancer; in Cameron JL (ed): *Current Surgical Therapy*, ed 6. Baltimore, Mosby, 1998, p 455.
- Shahib Y, El-Serag HB: The epidemiology of cholangiocarcinoma. *Semin Liver Dis* 2004;24:115–125.
- Burgos San Juan L: Cholangiocarcinoma (in Spanish). *Rev Med Chil* 2008;136:240–248.
- Rubel LR, Ishak KG: Thorotrast-associated cholangiocarcinoma. *Cancer* 1982;50:1408–1415.
- de Groen PC, Gores GJ, LaRusso NF, et al: Biliary tract cancers. *N Engl J Med* 1999;341:1368–1378.
- Jarnagin WR, Fong Y, DeMatteo RP, et al: Staging respectability, and outcome in 225 patients with hilar cholangiocarcinoma. *Ann Surg* 2001;234:507–519.
- Reed DN Jr, Vitale GC, Martin R, et al: Bile duct carcinoma: trends in treatment in the nineties. *Am Surg* 2000;66:711–715.
- Liu CL, Lo CM, Lai EC, et al: Endoscopic retrograde cholangio-pancreatography and endoscopic endoprosthesis insertion in patients with Klatskin tumors. *Arch Surg* 1998;133:293–296.
- Polydorou AA, Cairns SR, Dowsett JF, et al: Palliation of proximal malignant biliary obstruction by endoscopic endoprosthesis insertion. *Gut* 1991; 32:685–689.
- Ducreux M, Liguory C, Lefebvre JF, et al: Management of malignant hilar biliary obstruction by endoscopy: results and prognostic factors. *Dig Dis Sci* 1992;37:778–783.
- Farley DR, Weaver AL, Nagorney DM: 'Natural history' of unresected cholangiocarcinoma: patient outcome after noncurative intervention. *Mayo Clin Proc* 1995;70:425–429.
- Baer HU, Stain SC, Dennison AR, et al: Improvements in survival by aggressive resections of hilar cholangiocarcinoma. *Ann Surg* 1993;217:20–27.
- Devieere J, Baize M, de Toeuf J, et al: Long-term follow-up of patients with hilar malignant stricture treated by endoscopic internal biliary drainage. *Gastrointest Endosc* 1988;34:95–101.
- Gibson RN, Yeung E, Hadjis N, et al: Percutaneous transhepatic endoprosthesis for hilar cholangiocarcinoma. *Am J Surg* 1988;156:363–367.
- Lai EC, Tompkins RK, Mann LL, et al: Proximal bile duct cancer: quality of survival. *Ann Surg* 1987;205: 111–118.
- Havlik R, Sbisà E, Tullo A, et al: Results of resection for hilar cholangiocarcinoma with analysis of prognostic factors. *Hepatogastroenterology* 2000;47:927–931.
- Kapoor VK, Pradeep R, Haribhakti SP, et al: Intrahepatic segment III cholangiojejunostomy in advanced carcinoma of the gallbladder. *Br J Surg* 1996;83:1709–1711.
- Chaudhary A, Dhar P, Tomey S, et al: Segment III cholangiojejunostomy for carcinoma of the gallbladder. *World J Surg* 1997;21:866–871.
- Guthrie CM, Banting SW, Garden OJ, et al: Segment III cholangiojejunostomy for palliation of malignant hilar obstruction. *Br J Surg* 1994;81:1639–1641.
- Figueras J, Llado L, Valls C, et al: Changing strategies in diagnosis and management of hilar cholangiocarcinoma. *Liver Transpl* 2000;6:786–794.
- Blom D, Schwartz SI: Surgical treatment and outcome in carcinoma of the extrahepatic bile ducts: the University of Rochester experience. *Arch Surg* 2001;136:209–215.
- Smith AC, Dowse JF, Russell RC, Hatfield AR, Cotton PB: Randomized trial of endoscopic stenting versus surgical bypass in malignant low bile duct obstruction. *Lancet* 1994;344:1655–1660.

- 23 Davids PH, Groen AK, Rauws EA, Tytgat GN, Huibregtse K: Randomized trial of self-expanding metal stents versus polyethylene stents for distal malignant biliary obstruction. *Lancet* 1992;34:1488–1492.
- 24 Schmassmann A, von-Gunten E, Knuchel J, Scheurer U, Fehr HF, Halter F: Wall stents versus plastic stents in malignant biliary obstruction: effect of stent patency of the first and second stent on patient compliance and survival. *Am J Gastroenterol* 1996;91:654–659.
- 25 Born P, Rosch T, Bruhl K, Sandschin W, Weigert N, Ott R, et al: Long-term outcome in patients with advanced hilar bile duct tumors undergoing palliative endoscopic or percutaneous drainage. *Z Gastroenterol* 2000;38:483–489.
- 26 Peters RA, Williams SG, Lombard M, Karani J, Westaby D: The management of high grade hilar strictures by endoscopic insertion of self-expanding metal prostheses. *Endoscopy* 1997;29:10–16.
- 27 Prat F, Chapat O, Ducot B, Ponchon T, et al: A randomized trial of endoscopic drainage methods for inoperable malignant strictures of the common bile duct. *Gastrointest Endosc* 1998;42:76–80.
- 28 Van Groenigen CJ: Intravenous and intra-arterial chemotherapeutic possibilities in biliopancreatic cancer. *Ann Oncol* 1999;10:305–307.
- 29 Bowling TE, Galbraith SM, Hatfield AR, et al: A retrospective comparison of endoscopic stenting alone with stenting and radiotherapy in non-resectable cholangiocarcinoma. *Gut* 1996;39:852–855.
- 30 Baisden JM, Kahaleh M, Weiss GR, Sanfey H, Moskaluk CA, Yeaton P, de Lange EE, Rich TA: Multimodality treatment with helical tomotherapy intensity modulated radiotherapy, capecitabine, and photodynamic therapy is feasible and well tolerated in patients with hilar cholangiocarcinoma. *Gastrointest Cancer Res* 2008;2:219–224.
- 31 Ortner ME, Caca K, Berr F, et al: Successful photodynamic therapy for nonresectable cholangiocarcinoma: a randomized prospective study. *Gastroenterology* 2003;125:1355–1363.
- 32 Giuliano EA, Ota J, Tucker SA: Photodynamic therapy: basic principles and potential uses for the veterinary ophthalmologist. *Vet Ophthalmol* 2007;10: 337–343.
- 33 Henderson B, Waldow S, Mang T, et al: Tumor destruction and kinetics of cell death in tow experimental mouse tumors following photodynamic therapy. *Cancer Res* 1985;45:572–576.
- 34 Wong Kee Song LM, Wang KK, Zinsmeister AR: Mono-L-aspartyl chlorine e6 (NPe6) and hematoporphyrin derivative (HpD) in photodynamic therapy administered to a human cholangiocarcinoma model. *Cancer* 1998;82:421–427.
- 35 Zoepf T, Jakobs R, Arnold JC, et al: Palliation of nonresectable duct cancer: Improved survival after photodynamic therapy. *Am J Gastroenterol* 2005;100:2426–2430.
- 36 Kahaleh M, Mishra R, Shami V, et al: Unresectable cholangiocarcinoma: comparison of survival in biliary stenting alone versus stenting with photodynamic therapy. *Clin Gastroenterol Hepatol* 2008;6: 290–297.
- 37 Talreja JP, Sauer B, Ellen K, Rehan ME, Shami VM, Kahaleh M: Photodynamic therapy for unresectable cholangiocarcinoma: what is the contribution of single operator cholangioscopy for targeted Treatment? *Gastrointest Endosc* 2009;69:AB146.
- 38 Vauthey JN, Blumgart LH: Recent advances in the management of cholangiocarcinomas. *Semin Liver Dis* 1994; 14:109–114.
- 39 Prasad G, Wang K, Baron TH, et al: Factors associated with increased survival after photodynamic therapy for cholangiocarcinoma. *Clin Gastroenterol Hepatol* 2007;5:743–748.
- 40 Ortner MA, Liebethuth J, Schreiber S, et al: Photodynamic therapy of nonresectable cholangiocarcinoma. *Gastroenterology* 1998;114:536–542.
- 41 Berr F, Weidmann M, Taanapfel A, et al: Photodynamic therapy for advanced bile duct cancer: evidence for improved palliation and extended survival. *Hepatology* 2000;31:291–298.
- 42 Rumalla A, Baron TH, Wang KK, et al: Endoscopic application of photodynamic therapy cholangiocarcinoma. *Gastrointest Endosc* 2001;53:500–504.
- 43 Dumoulin FL, Gerhardt T, Fuchs S, et al: Phase II study of photodynamic therapy and metal stent as palliative treatment for nonresectable hilar cholangiocarcinoma. *Gastrointest Endosc* 2003;57:860–867.
- 44 Harewood GC, Baron TH, Rumalla A, et al: Pilot study to assess patient outcomes following endoscopic application of photodynamic therapy for advanced cholangiocarcinoma. *J Gastroenterol Hepatol* 2005;20: 415–420.
- 45 Witzigmann H, Berr F, Ringel U, et al: Surgical and palliative management and outcome in 184 patients with hilar cholangiocarcinoma: palliative photodynamic therapy plus stenting is comparable to r1/r2 resection. *Ann Surg* 2006;244:230.

Michel Kahaleh, MD, Director Pancreatico-Biliary Services
 Digestive Health Center Box 800708
 University of Virginia Health System
 Charlottesville, VA 22908–0708 (USA)
 Tel. +1 434 243 9259, Fax +1 434 924 0491, E-Mail mk5ke@virginia.edu