



ELSEVIER

INTERNATIONAL
JOURNAL OF SURGERY

www.theijs.com

REVIEW

Abdominal actinomycosis

J.P. Garner*, M. Macdonald, P.K. Kumar

Department of Surgery, Chesterfield Royal Hospital NHS Foundation Trust, Calow, Chesterfield,
North Derbyshire S44 5BL, UK

KEYWORDS

Actinomycosis;
Abdomen;
Malignancy;
Appendicitis;
Inflammatory bowel
disease;
Penicillin

Abstract Abdominal actinomycosis has been recognised for over 150 years yet remains largely unknown to most clinicians. Its varied presentations are usually considered to represent malignancy rather than an infective process – and was once described as '*the most misdiagnosed disease*'. Actinomyces are gram positive bacilli of the Actinomycetales genus, and *A. israelii* is responsible for the majority of human disease. They are normal commensal inhabitants of the human bronchial and gastrointestinal tracts and seem to only cause pathological infection after preceding mucosal breakdown. Patients who have undergone appendectomy, have had a missed perforated appendicitis or women with a history of intrauterine contraceptive device use are at an increased risk. Florid abscess formation with fistulation, abundant granulation and dense surrounding fibrosis are common. Diagnosis prior to, or even during, surgery is rare and the findings are usually mistaken for acute inflammatory pathologies or malignancy. The treatment of choice is prolonged antibiotic therapy, usually with penicillin to which the organisms remain exquisitely sensitive, although delayed recurrence is possible. This review outlines the historical background of actinomycetal infection and considers the epidemiology, pathophysiology and clinical features of abdominal actinomycosis.

© 2006 Surgical Associates Ltd. Published by Elsevier Ltd. All rights reserved.

Historical background

Abdominal actinomycosis was first described 31 years before actinomyces themselves were isolated. In 1846, Dr William Bradshaw reported a gentleman with a right iliac fossa mass which spontaneously discharged through the

skin; after a temporary response to potassium iodide therapy, the abscess recurred and the patient died. This first case of abdominal actinomycosis was appositely recalled by Sir Zachary Cope in his Bradshaw Memorial Lecture 'Visceral Actinomycosis' at the Royal College of Surgeons in 1949.¹ It was not until 1877 however that Bollinger isolated branching mycelia from lesions within the jaw bones of cattle² which were named '*Strahlenpilz*', meaning '*Ray fungus*', or *Actinomyces* in Greek; a misconception of their true nature that persisted for over 70 years. In 1878 Israel cultured similar mycelia to Bollinger using human tissues

* Corresponding author. 6 Kensington Court, Lodge Moor, Sheffield S10 4NL, UK. Tel.: +44 114 230 1237; fax: +44 1246 512 313.
E-mail address: jeffgarner@doctors.org.uk (J.P. Garner).

and noted it to be anaerobic. The following year Ponfick described the first named case of human actinomycosis¹ and thereafter a slow stream of cases entered the literature. In the latter years of the 19th Century two conflicting arguments as to the nature of actinomycal infection were proposed. Bostroem suggested actinomycetes were aerobic branching filamentous fungi occurring naturally in soils and on grasses and grains which must be ingested to cause pathological actinomycosis—the exogenous theory. The opposing endogenous view of Wolff and Israel supposed actinomycetes to be delicate anaerobes found only at body temperature in humans and animals.³ This debate continued for over 40 years until the reports of several investigators culminated in the work of Colebrook⁴ and Naeslund⁵ in 1931, who separately provided the evidence to confirm the endogenous theory. Actinomycetes species are prevalent in soil but not those that have been identified as causing disease in man.¹ Erickson differentiated between the human and animal strains of the organism and proposed the names *Actinomyces israelii* for the human form, and *Actinomyces bovis* for the cattle variant, although the differentiation between strains was rarely made until recently.⁶ Taxonomic studies have since confirmed Erickson's findings and confirmed Actinomycetes to be bacteria rather than fungi by virtue of their lack of nuclear membrane or cell wall chitin, reproduction by fission, insensitivity to amphotericin B and sensitivity to penicillin.⁷ They are classified within the genera *Actinomycetales* alongside nocardia, streptomycetes and mycobacteria.

Bacteriology

Actinomycetes species are gram positive bacteria, non-sporing absolute or facultative anaerobes that require anaerobic carbon dioxide rich medium for culture. The yield from standard cultures is poor and repeated sampling may be needed to obtain a positive culture although recent improvements in culture media have allowed significantly more actinomycetes species to be isolated.⁸ Subtyping by nitrate reduction, differential sugar metabolism and esculin hydrolysis has now largely been replaced by radio-immunofluorescence techniques. The predominant form in human disease is *A. israelii*,⁹ with occasional cases caused by *A. naeslundii*, *odontolyticus*, *viscosus* or *meyeri*.¹⁰ Typical cultures are 1–1.5 mm in diameter and have a 'bread crumb' appearance. Branching filamentous cells are common to all species of actinomycetes (Fig. 1), but only when present in sufficient numbers do *Actinomyces* species secrete the polysaccharide that bind the bacilli's branched filaments forming characteristic 'sulphur granules'. These are typically yellow, but can range in colour from white to brown.¹¹ They are commonly considered diagnostic of actinomycal infection, but are present in only 50% of cases.¹² They form only *in vivo* but may be mimicked by other bacteria from the *Actinomycetales* genus as well as occasional staphylococcal infection.⁷ All actinomycetes species remain sensitive to penicillin as well as most other common modern antibiotics — the aminoglycosides appear to be the only major group of antimicrobials with minimal activity against actinomycetes.⁶

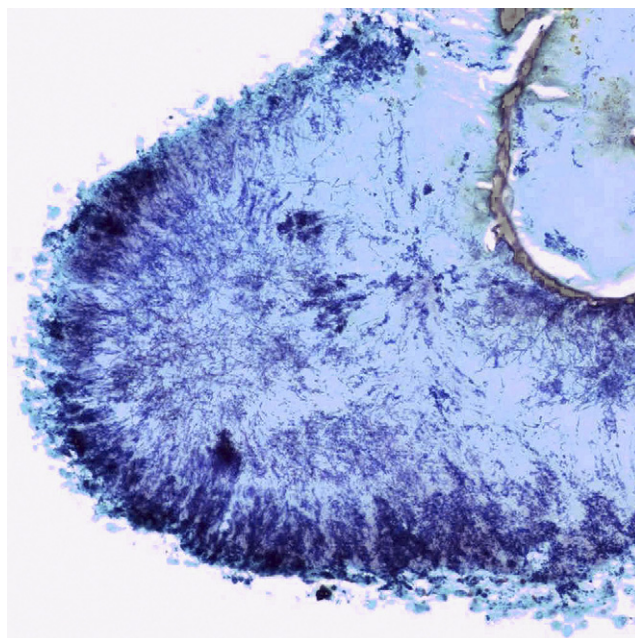


Figure 1 Abundant filamentous actinomycetes colonies. (Gram stain $\times 100$).

Epidemiology

Abdominal actinomycosis is approximately three times commoner in men than women, despite an increasing number of cases occurring in association with the use of intrauterine contraceptive devices (IUCDs). There is no correlation between the disease and place of residence, social class or ethnicity although early studies described a preponderance of cases in rural dwellers and agricultural workers,¹³ which undoubtedly fuelled the exogenous theory of disease propagation. Adolescence to middle age are the commonest ages affected mirroring the incidence of its commonest aetiology — perforated appendicitis.¹³ The overall incidence of actinomycosis is virtually impossible to ascertain as failure to consider it as a diagnosis and difficulties in confirming it lead to under-reporting: Cope 'knew of no disease which is so often missed by experienced clinicians'.¹ There are no recent estimates of disease prevalence but historically 20–40 cases were reported in the United Kingdom each year,¹⁴ the Mayo clinic reported 122 cases in 35 years,¹³ but a Russian report described over 2000 cases in 11 years.¹⁵ The estimated population prevalence is one case per 40–119,000 population⁹ and is thought to be decreasing.³

Pathology

A. israelii and other actinomycetes species are endogenous inhabitants of most human mucous membranes, with the mouth, bronchi and gastrointestinal tract most commonly populated. They inhibit areas of stasis and the tonsillar crypts in the mouth and appendix, caecum and sigmoid are the predominant gastrointestinal sites, although Naeslund failed to identify actinomycetes in any faecal samples

from asymptomatic individuals.⁵ He suggested that they appear in the gut by transit from the oral mucosa. Actinomyces do not inhabit the female genital tract in the absence of an IUCD.¹⁶ They are neither infective or transmissible and until recently have not been deemed a pathogen of the immunocompromised.¹⁷ The mechanism of pathological infection is unclear, but circumstantial evidence suggests that preceding mucosal injury is required before actinomycosis supervenes. Perforated appendicitis is the commonest cause with neoplasm or trauma, such as fishbone perforation of the gastrointestinal tract, also well documented.¹³ Occasional cases are reported where there is no preceding mucosal injury.¹⁸ An initial stage of localised abscess formation is followed by extension into spreading peritoneal disease. Finally the disease progresses into a stage of fistulization, both internally and cutaneously.¹⁹ The abscesses generally consist of a thick layer of granulation surrounding a central pool of pus. The granulation zone is highly cellular, including fibroblasts and collagen fibres and the central zone of pus contains the typical sulphur granules with occasional liquifaction. Actinomycotic infection is typified by a progressive inflammatory response which is contiguous and insidious with multiple connecting abscesses and an aggressive desmoplastic process.²⁰ Spread is rarely lymphatic or haematogenous.²¹ Polymicrobial superinfection is common, and it has been suggested that actinomyces are pathogenic only with the synergistic action of other bacteria. Holm examined the pus from over 600 actinomycotic lesions and in no cases were actinomyces identified in isolation. The other bacteria present varied according to the site of infection, with coliforms and gram negative bacilli tending to accompany abdominal cases.²²

Clinical features

Human actinomyceal infection commonly affects three areas. Most (>50%) are cervicofacial⁹ and are associated with poor oral hygiene and dentition.²³ It may present as a complication of dental extraction and is analogous to the bovine actinomyceal disease 'lumpy jaw'. Thoracic actinomycosis represents 15–20% of cases and may present as diffuse pulmonary infiltration or a discrete mass mimicking bronchial carcinoma.⁹ Abdominal actinomycosis accounts for approximately 20% of cases.²⁰ The remainder are sporadic cases involving organs as diffuse as the brain, salivary glands¹² and vertebra¹ or occasionally systemic disease.²⁴

The ileocaecal area

This is the abdominal site most commonly affected, with the appendix predominating. Desmukh et al reviewed 205 cases of abdominal actinomycosis and two thirds involved the appendix and caecum,²⁵ whilst Putman reported three quarters of his cases followed perforated appendicitis – it is rarely found in an inflamed but intact appendix.²⁶ It is presumed that the disruption of the inflamed appendix allows liberation of the actinomyces to initiate pathological actinomycosis; alternatively in some cases the very act of removing a normal appendix may be sufficient to trigger it.¹³ There is some geographical

variation, with the transverse colon being as common a site in a Japanese study.²⁷

The presentation of right iliac fossa actinomycosis is variable. The most common is one of inflammation with abdominal tenderness and guarding – a mass may be palpable. Careful examination may reveal the tenderness and mass to arise more from the right flank muscles than intraperitoneally as extension of right iliac fossa actinomycosis into the retroperitoneal muscles is common. If the symptoms arise *de novo* then the differential diagnosis includes acute appendicitis, an acute presentation of inflammatory bowel disease²⁰ or if a mass is the predominant feature the carcinoma of the caecum or ascending colon must also be considered. Careful history taking may disclose a similar upset 2–3 weeks previously suggestive of missed perforated appendicitis. Mild pyrexia and leukocytosis are common as is elevation of inflammatory markers. If the disease has been present for several weeks the mass may be fluctuant or show signs of enterocutaneous fistulation.²⁰

Colon

Actinomycosis of the colon between caecum and anorectum accounts for approximately 15% of all abdominal cases.²⁸ With the decrease in incidence of missed appendicitis because of earlier diagnosis, the incidence of ileocaecal actinomycosis is falling whereas colonic cases are on the increase. Since 1986 there have been at least 50 reported cases of colonic actinomycosis. The majority involve the sigmoid and left colon and occur with generalised pelvic actinomycosis after IUCD usage. The commonest presentation is with an obstructed left colon. The signs, symptoms and radiological appearances are largely indistinguishable from colonic adenocarcinoma. The dense fibrotic reaction of actinomycosis leads to stricturing with mass formation and the patient describes a change of bowel habit, bloating and occasional features of systemic upset such as anorexia and weight loss. At laparotomy there is an intense desmoplastic reaction engulfing the pelvis with the gynaecological organs densely adherent to the strictured colon.

Anorectum

Primary ano-rectal lesions are rare, with only 27 cases since 1968. It should be distinguished from extrinsic rectal stricturing from pelvic actinomycosis which is more prevalent. It presents as perianal abscess – often recurrent – or fistula-in-ano and may mimic the appearances of a Crohn's perineum.²⁹ Failure to consider the diagnosis of actinomycosis in recurrent perianal disease leads to chronicity – the mean duration of perianal symptoms in these 27 cases was 7½ years,³⁰ with one case having intermittent symptoms and repeated drainage procedures for 30 years before diagnosis.³¹ It appears to occur more commonly in the immunocompromised^{17,29} in contrast to the majority of actinomycosis. The presence of sulphur granules in the drained pus at operation suggests the correct diagnosis and treatment is by simple drainage and antibiotic therapy; setons are not usually not required.³⁰

Liver

The literature contains 68 cases of hepatic actinomycosis which are usually unilobar, but bilobar and multiple lesion disease have also been described.³² Direct extension into surrounding tissue seems particularly common in the liver; the diaphragm, stomach, pancreas and common bile duct may all become involved. Patients present with a low grade fever and non-specific symptoms of constitutional upset, weight loss, anorexia and malaise. Two thirds of cases are male and the mean duration of symptoms before diagnosis is four months.³³ Given the non-specific nature of the presentation, often suggesting biliary infection, ultrasound scanning is usually the first investigation. Identification of a hepatic abscess allows percutaneous drainage and non-operative diagnosis – achieved in 72% of cases of hepatic actinomycosis,³³ compared to a 10% non-operative detection rate for abdominal actinomycosis elsewhere.²⁵ The ultrasound appearances however are not diagnostic and 13/57 cases demonstrated solid hepatic lesions suggestive of a malignant process,³² consequently surgical resection still plays a part in diagnosis and management.

Biliary system

The 18th case of actinomycotic biliary disease has recently been reported³⁴ and the presenting features appear little different from 'ordinary' cholecystitis, although the subsequent cholecystectomy is complicated by the dense fibrotic adhesions typical of this disease. Gallstones dropped at routine laparoscopic cholecystectomy have also been implicated in causing retroperitoneal actinomycosis.³⁵ Involvement of the biliary ducts alone is also described,³⁶ as is a single case of coexistent actinomycosis and adenocarcinoma of the gallbladder.³⁷ The infective agent in both cases was *A. naeslundii*, which has been isolated in three other cases of acute actinomycotic cholecystitis.³⁸ Given the rarity of *A. naeslundii* infections elsewhere,³⁹ it suggests that this particular harmless oral cavity saprophyte has a predilection for pathogenesis within the biliary tree.

Pancreas, stomach and small intestine

Involvement of the stomach, pancreas and small bowel are all equally rare. There are only 5 reliable reports of

pancreatic actinomycosis, 2 of which involved colonisation of pancreatic stents by *A. meyeri*.⁴⁰ Gastric actinomycosis, of which there have been only 20 reported cases, presents similarly to gastric malignancy with weight loss, early satiety and anorexia,⁴¹ but there is often a fever and leucocytosis. It may follow bariatric or peptic ulcer surgery⁴² and an epigastric mass is commonly evident. CT scanning may show a diffuse heterogeneously enhancing mass lesion although differentiation from malignancy is impossible.

Isolated small bowel involvement is extremely rare,⁴³ although the small intestine may easily become involved in an actinomycotic mass elsewhere within the abdomen and present with obstruction or non-traumatic perforation.⁴⁴ Given the presumed necessity for mucosal injury prior to pathogenic actinomyceal infection, it is surprising that actinomycosis rarely complicates inflammatory bowel disease, with only one or two isolated case reports.⁴⁵

Genitourinary tract

Occasional cases of isolated renal⁴⁶ or ureteric⁴⁷ involvement are reported but external ureteric compression by widespread retroperitoneal or pelvic actinomycosis is much more common – hydronephrosis and obstructive nephropathy ensue (Fig. 2).⁴⁸ Stenting of the ureters may be sufficient to maintain renal function until antibiotic therapy resolves the inflammatory compression,⁴⁹ but ureteral resection and reconstruction may be required.⁵⁰ Primary bladder actinomycosis is equally rare, and presents with frequency, dysuria, haematuria or a suprapubic mass⁵¹ – sulphur granules in the urine may be the first clue as to the diagnosis.⁵² It may be mistaken for a vesical or even urachal tumour⁵³ and diagnosis and treatment without resection is uncommon. Primary testicular actinomycosis has been reported sporadically with the findings of often multiple firm testicular lesions being difficult to distinguish from primary or metastatic malignancy.⁵⁴ Orchidectomy may be the treatment of choice as it appears to remove the need for prolonged antibiotics.

The area of greatest interest at present is the clear association of actinomycosis with the use of IUCDS, an observation first made in 1928,⁵⁵ and seemingly forgotten for nearly 50 years.⁵⁶ Two large studies examining cervical smear samples show that actinomyceal colonisation of the female genital tract does not occur in the absence of

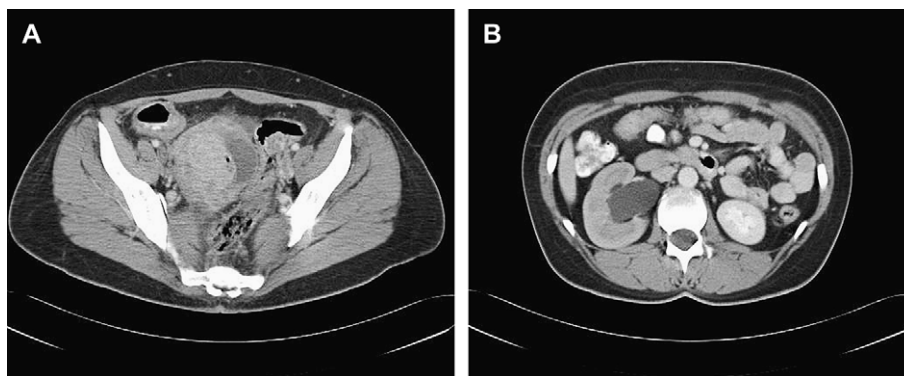


Figure 2 (A) Heterogeneous right ovarian mass with solid and cystic components also containing pockets of gas, causing a right hydronephrosis (B).

IUCD usage,^{16,57} whereas the colonisation rate – almost exclusively by *A. israelii* – in association with IUCD usage is up to 14.6%,⁵⁷ depending upon the type of IUCD in situ. The true incidence is probably somewhat less than this and Valicenti et al.'s¹⁶ study of nearly 70,000 women probably gives the most reliable indication. They found an incidence of proven actinomyceal colonisation of the female genital tract of 1.6% in IUCD wearers in the general population, rising to 5.3% in a subgroup of attendees to a family planning clinic. Actinomyces were not encountered without an IUCD in either group. The incidence of actinomycotic infection increases with duration of IUCD use⁵⁷ and the mean duration of coil usage in women with actinomycosis is 8 years.⁵⁸ The commonest presenting features are abdominal pain, weight loss, vaginal discharge and fever.⁵⁸ The reason for the association with IUCD usage is unclear. Insertion of the device may traumatise the cervical and uterine mucosa, creating the injury necessary for actinomyces to act pathogenically or the strings of the coil may interrupt the protective barrier formed by the cervical mucus and allow ascending infection.⁵⁹ Furthermore, disintegration of long term devices may cause distribution of small calcified fragments throughout the genital tract to act as a nidus for actinomyceal collection.⁵⁸ Lifestyle and variations in sexual behaviours may also contribute as it is suggested that orogenital sex may transmit oral actinomyces to the female genital tract.³⁹ A report from Taiwan observed that whilst there had been 136, 200 IUCD insertions there in the preceding two years alone, there had only been 3 reported cases of pelvic actinomycosis in 40 years.⁶⁰

Whilst IUCD usage predisposes to actinomyceal colonisation of the genital tract in substantial numbers of women, symptomatic pelvic actinomycosis is still rare. It is currently impossible to predict which 'colonised' women will go onto develop straightforward actinomyceal disease such as endometritis which will respond to antibiotics, or the even smaller number who will fall foul of widespread pelvic actinomycosis. It has been suggested that women found to harbour actinomyces on routine cervical smears should be offered antibiotic 'eradication' therapy or 4-yearly IUCD changes.⁶¹ Of more concern are the small but increasing

number of patients presenting with rectal⁶² or ureteric⁵⁰ strictures, or both,⁶³ from external compression by an actinomycotic mass appearing as a 'frozen pelvis'. A multi-disciplinary approach is required as pelvic malignancy of gynaecological origin is usually suspected (Fig. 3) and patients may undergo significant surgical procedures in pursuit of a 'curative' cancer resection. Scribner et al.⁶⁴ describe a patient who underwent abdominoperineal resection, total abdominal hysterectomy and bilateral salpingo-oophorectomy for a pelvic mass which turned out to be purely actinomycotic in origin.

Abdominal wall

Cutaneous fistula involving the abdominal wall in intraperitoneal actinomycosis is common, but isolated abdominal wall disease is much rarer with only 16 cases in the English literature. It typically presents as a slow growing mass that is readily mistaken for a muscular tumour;⁶⁵ alternatively a more rapidly developing superficial abscess may occur and the patient presents with fever and leucocytosis.⁶⁶ Occasional cases of cutaneous actinomyces carpeting the skin over a wide area have also been reported.⁶⁷ There may be an underlying history of trauma or IUCD usage, as three cases are described of primary abdominal wall actinomycosis without concomitant pelvic infection – the mode of dissemination is presumed to be haematogenous.⁶⁸ Fluctuant lesions require drainage and any suggestion of actinomyces in the resultant pus should instigate antibiotic therapy. Lesions that are simply drained may recur.⁶⁶ Hard sarcomatous lesions should undergo axial imaging to delineate their extent and any underlying extensions into the abdominal cavity before treatment by excision.

Diagnosis

Actinomycosis is a renowned mimic and apart from microbiological examination, no test is diagnostic. Malignancy is often the main differential diagnosis and investigation is usually directed at excluding it. Actinomycosis is rarely

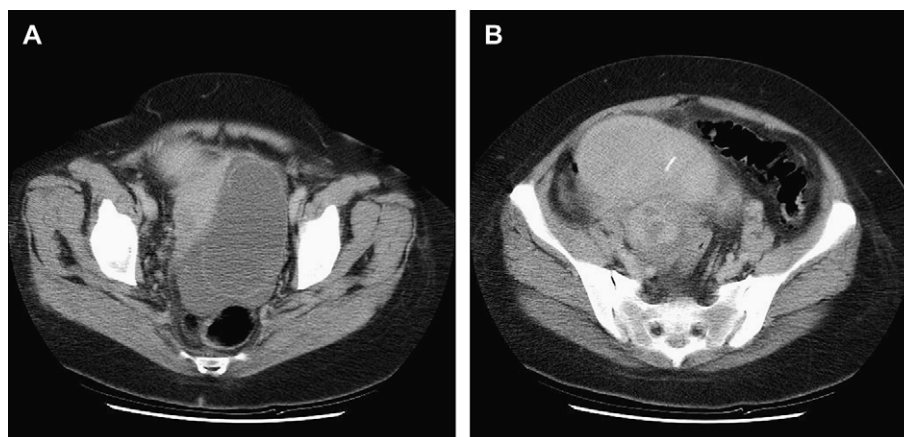


Figure 3 CT scans of a 52 year old lady who underwent total hysterectomy and bilateral salpingo-oophorectomy for the septated left ovarian cystic mass (A) and right sided solid/cystic mass (B) reported as most in keeping with ovarian carcinoma. A radio-opaque IUCD is visible in the uterus anteriorly.

considered in the differential; less than 10% of cases are diagnosed prior to surgery,²⁵ which is often not necessary if the correct diagnosis has been made.

Blood tests show a non-specific inflammatory picture compatible with malignancy and inflammatory bowel disease as well as actinomycosis and other infections. Plain abdominal radiology will only demonstrate the consequences of actinomycosis such as obstruction but offers no clue as to the cause. Ultrasound scanning can identify an abdominal mass and if consistent with an abscess then percutaneous drainage may be attempted,⁶⁹ it may however demonstrate the ultrasound features characteristic of a solid neoplasm. If pus is obtained, then the correct diagnosis can be made without surgery and antibiotic therapy commenced. In most cases this allows complete symptomatic resolution. Surgery is reserved for those that fail to respond to antibiotics or in whom more urgent relief of symptoms, such as colonic obstruction is required. Ultrasound scanning is the investigation of choice in patients with hepatobiliary symptoms and is more often diagnostic of hepatic actinomycosis than at other sites.

Barium enema examination may show a tapered luminal narrowing, mucosal fold thickening or mucosal nodularity, none of which are diagnostic and may be mistaken for malignancy⁹ or Crohns disease.⁷⁰ Computed tomographic (CT) scanning is the single most useful imaging modality. It reveals both the extent of inflammation and degree of organ involvement. Hydroureter from pelvic obstruction is clearly delineated by CT as are colonic strictures – whether intrinsic or extrinsic. Lee et al.⁷¹ reported universal bowel wall thickening in 18 cases of gastrointestinal actinomycosis. Seventeen were associated with a peri-colonic mass which were variously solid, cystic or a combination and generally enhanced after intravenous contrast reflecting the hypervascular nature of the inflammatory response.⁷² There was ureteric involvement in half of the cases. CT is also useful for solid organ actinomycosis, as the features of a solid/cystic mass lesion are present and CT guided drainage can be performed⁷³ Other modalities may be used with specific indications such as magnetic resonance imaging of the pelvis to delineate fistula-in-ano in perianal actinomycosis.⁷⁴ One or two cases of endoscopic detection of actinomycosis have been reported⁷⁵ but the appearances are non-specific although culture of retrieved specimens allows a non-operative diagnosis. In short no radiological, haematological or endoscopic investigation demonstrates any specific features to allow it to be diagnostic for abdominal actinomycosis although the infiltrative nature of the fibrotic process across different organs (ureters, sigmoid colon and tubo-ovarian structures), colonic thickening and mass formation on CT scanning are suggestive.

Treatment

As all actinomyces species remain sensitive to most common antibiotics the treatment of choice remains high dose antibiotic therapy for prolonged periods as the intense desmoplastic reaction associated with actinomycosis limits drug penetration. Therapy may be need for up to a year.⁷ The drug of choice is penicillin, 2.5–5 Megaunits, administered four times daily, parenterally in the first instance. In

penicillin-allergic individuals erythromycin and tetracycline are suitable alternatives. It has been reported that *A. naeslundii* is less susceptible to penicillin than *A. israelii* and erythromycin may then be considered as the first line agent.⁶ In cases that remain symptomatic after a month of penicillin therapy, consideration should be given to the use of additional antibiotics such as linozalid, because of the likelihood of polymicrobial superinfection.

It is usual for the correct diagnosis to be made only after pathological examination of a resected specimen, as even at open surgery it is difficult to positively identify a dense, fibrotic mass as actinomycotic in origin. In some situations it is claimed that surgical resection is the treatment of choice and that post operative antibiotic treatment is unnecessary.⁵⁴ This is not the case for intra-peritoneal disease where it may be difficult or mutilating to confidently resect all infected tissue. Actinomyceal infection can recur many years after initial treatment,⁷⁶ or may linger asymptotically if primary treatment is not curative, particularly when sites such as the retroperitoneum are involved. If the diagnosis is suspected at operation then it is possible to treat solely with antibiotics without surgical resection of tissue, but in most cases the similarities to carcinoma or inflammatory bowel disease are too great to consider leaving the inflammatory mass *in situ*. Resection of the infected, necrotic tissue is generally recommended to reduce the bacterial burden and lessen the chances of recurrence.

Summary

Abdominal actinomycosis remains an uncommon condition that mimics a wide variety of intra-abdominal complaints ranging from acute inflammatory pathologies such as appendicitis to colonic or gynaecological malignancy. Any abdominal organ may be affected. The possibility of actinomyceal infection should be borne in mind when dealing with atypical abdominal presentations, particularly if there is a previous history of appendiceal perforation or IUCD usage. Pre-operative diagnosis is often difficult and radiological imaging is unlikely to allow a definitive diagnosis. Surgical resection is frequently required coupled with high dose long-term antibiotics.

Acknowledgements

We are grateful to Dr Roger Start, Dr John Shortland and Dr James Hampton for their assistance with the figures for this review.

References

1. Cope Z. Visceral actinomycosis. *Br Med J* 1949;2:1311–6.
2. Bollinger O. Ueber sine neue Pilzkrankheit beim Rinde. *Centralb f.d. med Wissensch; Berl* 1877;15:481.
3. Berardi RS. Abdominal actinomycosis. *Surg Gynaecol Obstet* 1979;149:257–66.
4. Colebrook L. A report on 25 cases of actinomycosis. *Lancet* 1921;200:893.
5. Naeslund C. Experimentelle studien uber die aetiologie und pathogenese der Actinomycosis. *Acta Pathol Microbiol Scand* 1931;7(Suppl. 6):156.

6. Lerner PI. Susceptibility of pathogenic actinomycetes to antimicrobial compounds. *Antimicrob Agents Chemother* 1974;**5**:302–9.
7. Principles and practice of infectious diseases. In: Mandell GL, Douglas Jr RG, Bennett JE, editors. *Principles and practice of infectious diseases*. 2nd ed. New York: Churchill Livingstone; 1985.
8. Lewis R, McKenzie D, Bagg J, Dickie A. Experience with a novel selective medium for isolation of *Actinomyces* spp. from medical and dental specimens. *J Clin Microbiol* 1995;**33**(6):1613–6.
9. Cintron JR, Del Pino A, Duarte B, Wood D. Abdominal actinomycosis. Report of two cases and review of the literature. *Dis Colon Rectum* 1996;**39**:105–8.
10. Klaarborg KE, Kronberg O, Olsen H. Enterocutaneous fistulization due to *Actinomyces odontolyticus*: report of a case. *Dis Col Rectum* 1985;**28**:526–7.
11. Groves C. Johns Hopkins Medical Institutions. *Microbiol Newslett* 1996;**15**(30):1–2.
12. Weese WC, Smith IM. A study of 57 cases of actinomycosis over a 36-year period. *Arch Intern Med* 1975;**135**:1562–8.
13. Putman HC, Dockerty MB, Waugh JM. Abdominal actinomycosis. *Surgery* 1950;**28**:781–800.
14. Kolough F, Peltier LF. Actinomycosis. *Surgery* 1946;**20**:401.
15. Minsker OB, Yegorova TP. Studies on histogenesis of actinomycosis. *Mykosen* 1974;**17**:203.
16. Valicenti JF, Pappas AA, Graber CD, Williamson HO, Willis NF. Detection and prevalence of IUD-associated *Actinomyces* colonization and related morbidity. *JAMA* 1982;**247**:1149–52.
17. Fry RD, Birnbaum EH, Lacey DL. *Actinomyces* as a cause of recurrent perianal fistula in the immunocompromised patient. *Surgery* 1992;**111**(5):591–4.
18. Brown JR. Human actinomycosis; a study of 181 subjects. *Hum Pathol* 1973;**4**:319.
19. Mousseau PA, Mousseau-Brodu MC. L'actinomycosis abdominale. *J Chir (Paris)* 1973;**106**(6):565–88.
20. Postal A, Detry O, Louis E, Hardy N, Belaïche J, Jacquet N. Ileocaecal actinomycosis: report of a case simulating complicated inflammatory bowel disease. *Acta Gastroenterol Belg* 2001;**64**(4):318–20.
21. Grange JM. *Actinomyces*, nocardia and tropheryma. In: Grange JM, Greenwood D, Slack R, Penthener J, editors. *Medical microbiology*. 16th ed. London: Churchill Livingstone; 2002. p. 221–2.
22. Holm P. Studies on the aetiology of human actinomycosis – I: the other “microbes” of actinomycosis and their importance. *Acta Pathol Microbiol Scand* 1950;**27**:736.
23. Koren R, Dekel Y, Ramadan E, Veltman V, Dreznik Z. Periappendiceal actinomycosis mimicking malignancy: report of a case. *Pathol Res Pract* 2002;**198**:441–3.
24. Lawson E. Systemic actinomycosis mimicking pelvic malignancy with pulmonary metastasis. *Can Respir J* 2005;**12**(3):153–4.
25. Deshmukh N, Heaney SJ. Actinomycosis at multiple colonic sites. *Am J Gastroenterol* 1986;**81**(12):1212–4.
26. Orr KB. Actinomycosis. *Br Med J* 1973;**2**:664.
27. Matsumura K, Tanaka S, Ito T. A case of abdominal actinomycosis. *Nippon Geka Gakkai Zasshi* 1987;**88**(5):629–32.
28. Cowgill R, Quan SH. Colonic actinomycosis mimicking carcinoma. *Dis Colon Rectum* 1979;**22**(1):45–6.
29. Smith TR. Actinomycosis of the distal colon and rectum. *Gastrointest Radiol* 1992;**17**(3):274–6.
30. Coremans G, Margaritis V, Van Poppel HP, et al. Actinomycosis, a rare and unsuspected cause of anal fistulous abscess: report of three cases and review of the literature. *Dis Colon Rectum* 2005;**48**:575–81.
31. Shimada M, Kotani T, Ohtaki S, Tateno S, Tanigawa H, Katsuki T. Primary perianal actinomycosis over a thirty year period. *Jpn J Surg* 1986;**16**(4):302–4.
32. Lai AT, Lam CM, Ng KK, et al. Hepatic actinomycosis presenting as a liver tumour: case report and literature review. *Asian J Surg* 2004;**27**(4):345–7.
33. Sharma M, Briski LE, Khatib R. Hepatic actinomycosis: an overview of salient features and outcome of therapy. *Scand J Infect Dis* 2002;**34**:386–91.
34. Hefny AF, Torab FC, Joshi S, Sebastian M, Abu-Zidan FM. Actinomycosis of the gallbladder: case report and review of the literature. *Asian J Surg* 2005;**28**(3):230–2.
35. Ramia JM, Mansilla A, Villar J, Muffak K, Garrote D, Ferron JA. Retroperitoneal actinomycosis due to dropped gallstones. *Surg Endosc* 2004;**18**:345–9.
36. Hadley DA, Porschen RK, Juler GL. Actinomycosis of the common bile duct presenting as chronic cholecystitis. *Surgery* 1981;**90**:117–9.
37. Merle-Melet M, Mory F, Stempfel B, et al. *Actinomyces naeslundii*, acute cholecystitis and carcinoma of the gallbladder. *Am J Gastroenterol* 1995;**90**(9):1530–1.
38. Freland C, Massoubre B, Horeau JM, Caillon J, Drugeon HB. Actinomycosis of the gallbladder due to *Actinomyces naeslundii*. *J Infect* 1987;**15**:251–7.
39. Bonnez W, Latttmer G, Mohanraj NAC, Johnson TH. *Actinomyces naeslundii* as an agent of pelvic actinomycosis in the presence of an intrauterine device. *J Clin Microbiol* 1985;**21**(2):273–5.
40. Harsch IA, Benninger J, Niedobitek G, et al. Abdominal actinomycosis: complication of endoscopic stenting in chronic pancreatitis. *Endoscopy* 2001;**33**:1065–9.
41. Lee CM, Ng SH, Wan YL, Tsai CH. Gastric actinomycosis. *J Formos Med Assoc* 1996;**95**(1):66–8.
42. Fernandez-Acenero MJ, Silvestre V, Fernandez-Roldan R, Cortes L, Garcia-Blanch G. Gastric actinomycosis: a rare complication after gastric bypass for morbid obesity. *Obes Surg* 2004;**14**:1012–5.
43. Belak J, Boor A, Simon R, et al. Actinomycosis of the small intestine – an unusual cause of acute abdomen. *Rozhl Chir* 2001;**80**:602–4.
44. Leijonmarck CE, Fenyo G, Raf L. Non-traumatic perforation of the small intestine. *Acta Chir Scand* 1984;**150**(5):405–11.
45. Manley PN, Dhru R. Actinomycosis complicating Crohn's disease. *Gastroenterology* 1980 Nov;**79**(5 Pt 1):934–7.
46. Abe F, Tateyama M, Ommura Y, Ohashi K. Renal actinomycosis associated with a duodenorenal fistula caused by foreign body. *Acta Pathol Jpn* 1984;**34**(2):411–5.
47. Rubio Tortosa I, Sanchez Sanchis M, Coronel Sanchez B, et al. Ureteral actinomycosis. Case report. *Arch Esp Urol* 2005;**58**:351–3.
48. de Feiter PW, Soeters PB. Gastrointestinal actinomycosis: an unusual presentation with obstructive uropathy: report of a case and review of the literature. *Dis Colon Rectum* 2001;**44**:1521–5.
49. Ord J, Mishra V, Hudd C, Reginald P, Charig M. Ureteric obstruction caused by pelvic actinomycosis. *Scand J Urol Nephrol* 2002;**36**(1):87–8.
50. Bercovich A, Guy M, Karayiannakis AJ, et al. Ureteral obstruction and reconstruction in pelvic actinomycosis. *Urology* 2003;**61**:224.
51. Lee KR, Ko YS, Yu JW, Yoon CY, Kim CH, Yoon DK. Primary vesical actinomycosis: a case diagnosed by multiple trans-abdominal needle biopsies. *J Korean Med Sci* 2002;**17**:121–49.
52. Wajszczuk CP, Logan TF, Pasculle AW, Ho M. Intra-abdominal actinomycosis presenting with sulfur granules in the urine. *Am J Med* 1984;**77**(6):1126–8.
53. Gotoh S, Kura N, Nagahama K, et al. Actinomycosis of urachal remnants. *J Urol* 1988;**140**(6):1534–5.
54. Lin CY, Jwo SC, Lin CC. Primary testicular actinomycosis mimicking metastatic tumor. *Int J Urol* 2005;**12**:519–21.

55. Shivanagi SS, Deshpande NR. Pelvic actinomycosis associated with appendicitis and mucocele. *J Indian Med Assoc* 1977; **68**(8):169–70.
56. Gupta PK, Hollander DH, Frost JK. Actinomycetes in cervico-vaginal smears: an association with IUD usage. *Acta Cytol* 1976; **20**:295–7.
57. Chatwani A, Amin-Hanjani S. Incidence of actinomycosis associated with intrauterine devices. *J Reprod Med* 1994; **39**:585–7.
58. Duguid HL. Actinomycosis and IUDs. *IPPF Med Bull* 1983; **17**:1–2.
59. Santa MC, Buschmann BO, Daniel SJ. Actinomyces infection associated with intra-uterine device. *J Med Assoc State Ala* 1978; **47**(11):31–3.
60. Hsu CT, Roan CH, Rai SY, et al. Actinomycosis affecting the fallopian tube and ovary: report of 3 cases, with special reference to 2 cases following IUD application. *Asia Oceania J Obstet Gynaecol* 1988; **14**:275–84.
61. Evans DT. *Actinomyces israelii* in the female genital tract: a review. *Genitourin Med* 1993; **69**(1):54–9.
62. Ratliff DA, Carr N, Cochrane JP. Rectal stricture due to actinomycosis. *Br J Surg* 1986; **73**(7):589–90.
63. Nasu K, Matsumoto H, Yoshimatsu J, Miyakawa I. Ureteral and sigmoid obstruction caused by pelvic actinomycosis in an intra-uterine contraceptive device user. *Gynaecol Obstet Invest* 2002; **54**(4):228–31.
64. Scribner Jr DR, Baldwin J, Johnson GA. Actinomycosis mimicking a pelvic malignancy. A case report. *J Reprod Med* 2000; **45**: 515–8.
65. Lau WY, Boey J, Fan ST, Chan YF. Primary actinomycosis of the abdominal wall. *Aust N Z J Surg* 1986; **56**(11):873–5.
66. Gupta SK, Shukla VK, Khanna S. Primary actinomycotic mycetoma of the anterior abdominal wall (a case report). *J Postgrad Med* 1990; **36**:175–7.
67. Fazeli MS, H Bateni H. Actinomycosis: a rare soft tissue infection. *Dermatol Online J* 2005; **11**(3):18.
68. Hefny AF, Joshi S, Saadeldin YA, Fadlalla H, Abu-Zidan FM. Primary anterior abdominal wall actinomycosis. *Singapore Med J* 2006; **47**(5):419–21.
69. Goldwag S, Abbitt PL, Watts B. Case report: percutaneous drainage of periappendiceal actinomycosis. *Clin Radiol* 1991; **44**:422–4.
70. Pringot J, Bodart P. Inflammatory disease. In: Margulis A, Burhenne J, editors. *Alimentary tract radiology*. 4th ed. St Louis: Mosby; 1989. p. 759–815.
71. Lee I-J, Ha HK, Park CM, et al. Abdominopelvic actinomycosis involving the gastrointestinal tract: CT features. *Radiology* 2001; **220**:76–80.
72. Ha HK, Lee HJ, Kim H, Ro HJ. Abdominal actinomycosis: CT findings in 10 patients. *Am J Roentgenol* 1993; **161**:791–4.
73. Granger JK, Houn HY. Diagnosis of hepatic actinomycosis by fine-needle aspiration. *Diagn Cytopathol* 1991; **7**(1):95–7.
74. Cuenod CA, de Parades V, Siauve N, et al. MR imaging of ano-perineal suppurations. *J Radiol* 2003; **84**(4):516–28.
75. Piper MH, Schaberg DR, Ross JM, Shartsis JM, Orzechowski RW. Endoscopic detection and therapy of colonic actinomycosis. *Am J Gastroenterol* 1992; **87**(7):1040–2.
76. Moosmayer S. Abdominal actinomycosis. Actinomycotic abscess 10 years after appendectomy. *Tidsskr Nor Laegeforen* 1992; **112**(22):2857–8.